


# Perpustakaan Um Surabaya

## artikel 4 FK

 Quick Submit Quick Submit Universitas Muhammadiyah Surabaya

---

### Document Details

**Submission ID****trn:oid:::1:3224647376****Submission Date****Apr 22, 2025, 2:58 PM GMT+7****Download Date****Apr 22, 2025, 3:25 PM GMT+7****File Name****14366-47405-1-PB.pdf****File Size****521.3 KB****12 Pages****5,625 Words****32,524 Characters**

# 14% Overall Similarity

The combined total of all matches, including overlapping sources, for each database.





## Filtered from the Report

- Internet sources
- Publications




## Exclusions

- 4 Excluded Sources
- 3 Excluded Matches

## Match Groups

-  **24 Not Cited or Quoted 8%**  
Matches with neither in-text citation nor quotation marks
-  **0 Missing Quotations 0%**  
Matches that are still very similar to source material
-  **14 Missing Citation 6%**  
Matches that have quotation marks, but no in-text citation
-  **0 Cited and Quoted 0%**  
Matches with in-text citation present, but no quotation marks

## Top Sources

- 0%  Internet sources
- 0%  Publications
- 14%  Submitted works (Student Papers)

## Integrity Flags

### 0 Integrity Flags for Review

No suspicious text manipulations found.

Our system's algorithms look deeply at a document for any inconsistencies that would set it apart from a normal submission. If we notice something strange, we flag it for you to review.

A Flag is not necessarily an indicator of a problem. However, we'd recommend you focus your attention there for further review.

## Match Groups

- 24 Not Cited or Quoted 8%**  
Matches with neither in-text citation nor quotation marks
- 0 Missing Quotations 0%**  
Matches that are still very similar to source material
- 14 Missing Citation 6%**  
Matches that have quotation marks, but no in-text citation
- 0 Cited and Quoted 0%**  
Matches with in-text citation present, but no quotation marks

## Top Sources

- 0% Internet sources
- 0% Publications
- 14% Submitted works (Student Papers)

## Top Sources

The sources with the highest number of matches within the submission. Overlapping sources will not be displayed.

<b>1</b>	Student papers	
University College London		1%
<b>2</b>	Student papers	
University of Newcastle upon Tyne		1%
<b>3</b>	Student papers	
Brown University		<1%
<b>4</b>	Student papers	
University of East London		<1%
<b>5</b>	Student papers	
London School of Hygiene and Tropical Medicine		<1%
<b>6</b>	Student papers	
iHeed		<1%
<b>7</b>	Student papers	
University of Glamorgan		<1%
<b>8</b>	Student papers	
University of Leeds		<1%
<b>9</b>	Student papers	
University of New South Wales		<1%
<b>10</b>	Student papers	
Australian National University		<1%

11	Student papers	London Metropolitan University	<1%
12	Student papers	University of Central Florida	<1%
13	Student papers	Imperial College of Science, Technology and Medicine	<1%
14	Student papers	University Of Tasmania	<1%
15	Student papers	Chester College of Higher Education	<1%
16	Student papers	Udayana University	<1%
17	Student papers	University of Glasgow	<1%
18	Student papers	Capella University	<1%
19	Student papers	University of Leicester	<1%
20	Student papers	Pennsylvania State System of Higher Education	<1%
21	Student papers	Technological University Dublin	<1%
22	Student papers	University of Nottingham	<1%
23	Student papers	Angeles University Foundation	<1%
24	Student papers	The University of Texas at Arlington	<1%

25	Student papers	
University of Brighton		<1%
26	Student papers	
University of Cape Town		<1%
27	Student papers	
Flinders University		<1%
28	Student papers	
University of Wales, Bangor		<1%
29	Student papers	
Curtin University of Technology		<1%
30	Student papers	
Polytechnic of Turin		<1%
31	Student papers	
Collin County Community College		<1%



## Differences in Chest X-ray Imaging in Pulmonary Tuberculosis across Various Comorbidities

Mohammad Subkhan<sup>1</sup>, Meltritanian Arief Rezacharawa<sup>2</sup>, Muslim Andala Putra<sup>3</sup>, Afrita Amalia Laitupa<sup>4</sup>, Putu Bagus Dharma Permana<sup>5</sup>, Laily Irfana<sup>6</sup>

<sup>1,4</sup>Department of Respiriology and Pulmonology, Faculty of Medicine, Universitas Muhammadiyah Surabaya, East Java, Indonesia

<sup>2</sup> Faculty of Medicine, Universitas Muhammadiyah Surabaya, Surabaya, East Java, Indonesia

<sup>3</sup>Department of Radiology, Faculty of Medicine, Universitas Muhammadiyah Surabaya, East Java, Indonesia

<sup>5</sup> Faculty of Medicine, Universitas Airlangga, Surabaya, East Java, Indonesia

<sup>6</sup>Department of Neurology, Faculty of Medicine, Universitas Muhammadiyah Surabaya, East Java, Indonesia

<sup>1,3,6</sup> Siti Khodijah Muhammadiyah Sepanjang Hospital, Sidoarjo, East Java, Indonesia

Article Info	Abstract
<p><b>Article history:</b>  Received 18 March 2024  Revised 18 June 2024  Accepted 12 August 2024  Available online 18 August 2024</p> <p><b>Keywords:</b>  Pulmonary tuberculosis;  comorbidity; diabetes  mellitus; COPD; chronic  kidney disease</p> <p><b>Correspondence:</b>  mohammad.subkhan@um-sura-  baya.ac.id</p> <p><b>How to cite this article:</b>  Mohammad Subkhan, Meltritanian Arief  Rezacharawa, Muslim Andala Putra,  Afrita Amalia Laitupa, Putu Bagus  Dharma Permana, Laily Irfana. Differ-  ences in Chest X-ray imaging in Pulmo-  nary Tuberculosis across Various  Comorbidities. MAGNA MEDIKA  Berk Ilm Kedokt dan Kesehat. 2024;  11(2):169-180</p>	<p><b>Background:</b> Tuberculosis (TB) remains a significant public health concern in Indonesia, with a high prevalence of cases, particularly in patients with comorbidities such as HIV infection, chronic obstructive pulmonary disease (COPD), diabetes mellitus (DM), and chronic kidney disease (CKD). Evidence suggested radiological variations in chest X-ray findings among these complex conditions, which may pose significant challenges in accurately diagnosing pulmonary TB in clinical practice.</p> <p><b>Objective:</b> This study aimed to provide a comprehensive understanding of the variations in chest X-ray imaging in pulmonary TB patients with specific comorbidities, focusing on DM, CKD, and COPD.</p> <p><b>Methods:</b> A cross-sectional study was conducted at Siti Khodijah Muhammadiyah Sepanjang Hospital using standardized medical records and chest X-ray results of 50 pulmonary patients with comorbidities.</p> <p><b>Results:</b> The most prevalent comorbidity was DM, with radiological findings including fibro infiltrates, consolidations, and cavities. CKD patients exhibited radiological features such as fibroinfiltrates, cavitations, and pleural effusion, while COPD patients presented with fibroinfiltrates and consolidations.</p> <p><b>Conclusion:</b> The study provides valuable insights into the radiological manifestations of pulmonary TB and its comorbidities. It offers a basis for improved management and treatment strategies for patients with pulmonary TB and comorbidities. Further research employing longitudinal designs and a balanced representation of comorbid conditions is recommended to enhance understanding of the interplay between TB and associated health conditions.</p>

2024 MAGNA MEDIKA: Berkala Ilmiah Kedokteran dan Kesehatan with CC BY NC SA license

## INTRODUCTION

Tuberculosis (TB) has become a significant public health issue in Indonesia, with the country ranking second highest globally in TB cases.<sup>1</sup> TB is an infectious disease caused by *Mycobacterium tuberculosis*, primarily affecting the lungs but also capable of affecting multiple organs. WHO reports that globally, 10 million people suffer from TB annually, resulting in 1.2 million deaths.<sup>2</sup> In Indonesia, an estimated 845,000 individuals are affected by TB, with 98,000 deaths annually.<sup>1</sup> In Sidoarjo, the number of pulmonary TB cases has risen, reaching 157.37 per 100,000 population in 2019 compared to 113 deaths in 2018.<sup>3</sup>

The prevalence of TB increases among patients with comorbidities, particularly those with HIV infection, diabetes mellitus (DM), and chronic kidney disease (CKD).<sup>4</sup> Comorbidity refers to the Presence of additional diseases alongside the primary condition. Research conducted in 2016-2017 by Syarifah Miftahul *et al.* found a 19.4% prevalence of pulmonary TB among HIV patients at Ketergantungan Obat Hospital (RSKO) in Jakarta.<sup>5</sup> Among them, males had a higher prevalence of HIV-TB at 76.2%. Complications of TB with diabetes mellitus are also noteworthy, with Kottarath *et al.* reporting a 19.6% complication rate. Diabetes mellitus represents a global epidemic impacting both developed and developing nations, with an estimated 15% of TB patients experiencing comorbidities with diabetes mellitus.<sup>6,7</sup> Conversely, the occurrence of TB alongside CKD is relatively minimal.<sup>8-10</sup>

Diagnosing tuberculosis may involve various methods such as chest X-rays, CT scans, Mantoux or Tuberculin skin tests, and Interferon

Gamma Release Assays (IGRA).<sup>11</sup> A study indicates that pulmonary TB patients with DM tend to exhibit more severe chest symptoms compared to those without.<sup>12</sup> Additionally, evidence highlighted common radiological abnormalities among pulmonary TB patients, which include cloud-like shadows, cavities, and fibrosis. Routine chest X-rays for HIV-TB patients also revealed interesting anatomical distinctions, in which fibro infiltrate was predominant in the middle and lower lung regions when CD4+ levels were  $\leq 200$  cells/ $\mu$ L.<sup>13-15</sup>

Acquiring chest X-rays using the posterior-anterior (PA) projection is imperative. Pulmonary tuberculosis (TB) presents distinct radiographic manifestations categorized as primary and post-primary (secondary) TB. Radiological features of TB evident on chest X-ray examinations include primary TB signs such as peripheral pneumonic Consolidation (Ghon focus) with associated hilar lymphadenopathy (primary complex), typically resolving with calcification and small to extensive consolidations affecting one or more lobes of the lung. Post-primary TB signs include consolidations or patches in the superior lobes/apical regions of the inferior lobes, often accompanied by cavitation, pleural effusion, pleural thickening, or empyema, and miliary TB characterized by discrete 1-2 mm nodules disseminated throughout the lung fields due to hematogenous spread. Additionally, findings such as infiltrates, representing fine opaque thread-like opacities typically seen at lung apices, consolidations involving most of the upper or lower lung parenchyma, often with indistinct borders and air bronchograms, pleural effusion indicating an imbalance in pleural fluid formation and drainage cavitations displaying round radiolucent lesions without lung markings, sometimes

with fluid levels, and tuberculomas, well-defined focal masses resulting from *M. tuberculosis* infection and representing a more severe form of tuberculosis morphology, may be encountered.<sup>13-15</sup>

This study marks a pioneering endeavor, demanding a concentrated examination of chest X-ray interpretations among pulmonary tuberculosis patients with concurrent comorbidities. It aims to elucidate the correlation between tuberculosis and comorbidities in exacerbating lung damage, as evidenced by chest X-ray findings. Drawing from secondary data obtained from patient's medical records and chest X-rays, this research endeavors to unveil nuanced insights into the interaction between tuberculosis and comorbid conditions. This study aims to comprehensively understand the complex interplay between tuberculosis and comorbidities by leveraging existing data, informing more targeted interventions and improving patient outcomes.

## METHODS

### Study Design and Setting

This cross-sectional study was conducted in July 2023 at Siti Khodijah Muhammadiyah Sepanjang (SKMS) Hospital. The methodology and reporting of the study adhere to the Strengthening the Reporting of Observational Studies in Epidemiology (STROBE) Guidelines for cross-sectional studies.<sup>16</sup>

### Study Population

Standardized medical records documenting pulmonary TB cases in SKMS Hospital were collected by consecutive sampling technique and screened based on the following inclusion

and exclusion criteria: Inclusion Criteria: Newly diagnosed pulmonary TB patients who have undergone chest X-ray and Tuberculosis Culture Medium (TCM) or Acid-Fast Bacilli (AFB) examination, Pulmonary TB patients within the time frame of 2017 – July 2023, Pulmonary TB patients with comorbidities such as DM, HIV, SLE, CKD, and COPD, with supporting tests including NAAT and chest X-ray. Exclusion Criteria: Pulmonary TB patients with multi-drug resistant (MDR) TB, as well as patients who have failed therapy and recurrent cases.

### Data Collection

The data extracted from each eligible medical record included demographic information such as sex and age, as well as details on comorbidities and radiological findings from chest X-rays of pulmonary TB. These samples were obtained from secondary data available in medical records, laboratory, and radiology data from January 2018 to July 2023. After receiving the samples, the radiological findings were analyzed by three specialist radiologists and then evaluated. The study's results included patient name, age, gender, medical record number, radiological images, and comorbidities.

### Operational Definitions of Variables

Comorbidity refers to the Presence of additional medical conditions or diseases alongside pulmonary tuberculosis, regardless of whether they preceded TB or manifested concurrently. The comorbidity being sought in this study include diabetes mellitus (DM), chronic obstructive pulmonary disease (COPD), and chronic kidney disease (CKD):



Diabetes Mellitus (DM): Fasting Plasma Glucose (FPG)  $\geq 126$  mg/dL on two separate occasions OR, Hemoglobin A1c (HbA1c)  $\geq 6.5\%$  on two separate occasions OR, Oral Glucose Tolerance Test (OGTT) with plasma glucose  $\geq 200$  mg/dL two hours after a 75g oral glucose load OR, Classic symptoms of hyperglycemia or hyperglycemic crisis with a random plasma glucose  $\geq 200$  mg/dL, Chronic Kidney Disease (CKD): Estimated Glomerular Filtration Rate (eGFR)  $< 60$  mL/min/1.73m<sup>2</sup> for three months or more, with or without evidence of kidney damage OR Kidney damage markers such as albuminuria (albumin-to-creatinine ratio (ACR)  $\geq 30$  mg/g) or urine sediment abnormalities OR Imaging abnormalities suggestive of structural kidney disease for three months or more, with or without eGFR  $< 60$  mL/min/1.73m<sup>2</sup>, Chronic Obstructive Pulmonary Disease (COPD): Post-bronchodilator forced expiratory volume in one second (FEV1) to forced vital capacity (FVC) ratio (FEV1/FVC)  $< 0.70$ , indicating airflow limitation that is not fully reversible OR Presence of chronic respiratory symptoms such as dyspnea, chronic cough, and sputum production OR History of exposure to risk factors such as smoking, occupational pollutants, or biomass fuel smoke, in addition to compatible clinical findings and imaging studies consistent with COPD.

The radiological findings on chest X-rays were validated subjectively, relying on the conclusions provided by three radiologists' notes, which include fibro-infiltrate (FI), Consolidation (CON), Cavity (CAV), pleural effusion (PE), and Tuberculoma (T): Fibro-infiltrate: refined thread-like radiopaque appearance, Consolidation: a complication resulting from bronchial erosion and bronchogenic spread of

pulmonary TB disease due to bronchial compression caused by parenchymal abnormalities, including changes in volume with somewhat blurred margins and sometimes visible air-bronchogram. Consolidation predominantly involves either the upper or lower lung; pleural effusion: an excess of fluid in the pleural space indicating an imbalance between pleural fluid formation and drainage. Cavity: a cavity in the lung formed due to lung tissue damage. Cavitary appearance presents as a round image with radiolucency without lung markings. Sometimes, cavities can contain fluid, resulting in an air-fluid level appearance. Tuberculoma (tuberculosis granuloma) is a well-defined focal mass resulting from M. tuberculosis infection, representing one of the more severe morphological forms of tuberculosis.

### Statistical Analysis

The data analysis process in this study was performed using GraphPad Prism version 9.5.1 for MacOS (GraphPad Software, Boston, Massachusetts, USA). Descriptive statistics analysis for contingency was conducted to identify the frequency (N) and percentage (%) of the chest X-ray findings across different pulmonary TB comorbidities. A donut chart was generated to visualize the proportion and distribution of the results.

### Ethical Clearance

The research protocol of this study has been approved by the Health Research Ethics Committee of SKMS Hospital on 06 July 2023 with a reference number of 013/KET-KEPK/7-2023.

## RESULTS

### Baseline Characteristics

Two hundred and twenty-three (223) secondary data from TB patients with comorbidity were initially retrieved before the screening. After the exclusion of 173 samples due to the absence of the predetermined comorbidity among patients, the sample size was reduced to 50. A total of 50 pulmonary TB patients with other comorbidities were then subsequently included in the analysis. The average age of the study samples was 55.94 years (SD 10.56), with the majority being male (82%). The predominant comorbidity among pulmonary TB patients was diabetes mellitus (DM), comprised of 43 individuals (86%). Additionally, four pulmonary TB patients (8%) had chronic obstructive pulmonary disease (COPD). One individual (2%) each presented with other comorbidities, including chronic kidney disease (CKD), DM, and COPD, as well as DM and CKD (Table 1).

### Chest X-Ray Findings

The most common radiological chest X-ray findings among pulmonary TB patients with DM was fibroinfiltrate and Consolidation (33.33%), followed by fibroinfiltrate only (26.67%). In their chest X-ray results, a small part of pulmonary TB patients with DM also exhibited Cavity alongside fibroinfiltrate and Consolidation (11.11%). Fibroinfiltrate only and its combination alongside Consolidation were the radiological chest X-ray found in pulmonary TB patients with COPD, with the former being the more prevalent (60% vs 40%). Two radiological chest X-ray findings were distributed to each of the two pulmonary TB cases with CKD, including fibroinfiltrate and

Consolidation as well as fibroinfiltrate, Cavity, and pleural effusion (Table 2; Fig. 1). This study also identified radiographic descriptions of TB patients with dual comorbidities, namely TB with diabetes mellitus (DM) and chronic obstructive pulmonary disease (COPD), and TB with DM and chronic kidney disease. In cases of TB with DM and COPD, only infiltrates were observed, whereas TB patients with DM and chronic kidney failure exhibited both infiltrates and consolidations on radiographs.

## DISCUSSION

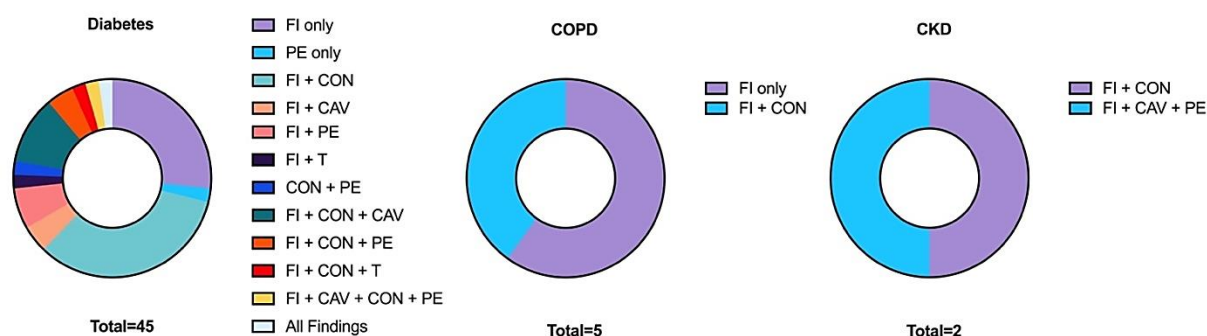
In general, the clinical manifestation of pulmonary TB can be influenced by three major factors, including the MTB agent (virulence factors), host (nutrition, host immune response), and environment (treatment being given, nearby residence). The pathogenic process of pulmonary TB involves several virulence factors, including a high mycolic acid content in the bacterial outer capsule, which hinders phagocytosis by alveolar macrophages. During the infection process, two main morphological changes occur in macrophages: the formation of multinucleated giant cells and epithelioid cells. Giant cells are conglomerates of fused macrophages that enhance phagocytosis. These giant cells and surrounding lymphocytes and other cells form granulomas around Mycobacterium particles. Over time, these granulomas expand but undergo an impaired healing process through macrophage-mediated phagocytosis of the bacteria, leading to fibrosis in the affected areas. As bacterial numbers increase, macrophages accumulate in specific lung regions, resulting in caseous necrosis and, eventually, lung cavities.

**Table 1.** Baseline Characteristics (Total=50)

Variable	N (%)
Sex	
Male	41 (82%)
Female	9 (18%)
Age (y), mean±SD	55.94±10.56
Comorbidities	
Diabetes Mellitus	43 (86%)
COPD	4 (8%)
CKD	1 (2%)
Diabetes Mellitus and COPD	1 (2%)
Diabetes Mellitus and CKD	1 (2%)

**Table 2.** Chest X-Ray Findings Across Different Comorbidities

CXR Findings in Comorbidity	N (%)
DM (Total=45)	
Fibroinfiltrate only	12 (26.67%)
Pleural Effusion only	1 (2.22%)
Fibroinfiltrate and Consolidation	15 (33.33%)
Fibroinfiltrate and Cavity	2 (4.44%)
Fibroinfiltrate and Tuberculoma	1 (2.22%)
Consolidation and Pleural Effusion	3 (6.67%)
Fibroinfiltrate, Consolidation, and Cavity	5 (11.11%)
Fibroinfiltrate, Consolidation, and Pleural Effusion	2 (4.44%)
Fibroinfiltrate, Consolidation, and Tuberculoma	1 (2.22%)
Fibroinfiltrate, Cavity, Consolidation, and Tuberculoma	1 (2.22%)
All Findings*	1 (2.22%)
COPD (Total=5)	
Fibroinfiltrate only	3 (60%)
Fibroinfiltrate and Consolidation	2 (40%)
CKD (Total=2)	
Fibroinfiltrate and Consolidation	1 (50%)
Fibroinfiltrate, Cavity, and Pleural Effusion	1 (50%)

**Figure 1.** Donut Chart of Chest X-Ray Findings in TB Patients with Diabetes Mellitus, COPD, and CKD. Abbreviations: FI: fibro-infiltrate; PE: pleural effusion; CON: consolidation; CAV: cavity; T: tuberculoma

However, pulmonary TB can also present atypical lung manifestations, especially in those with comorbidities such as HIV/AIDS, which demonstrate altered patterns of infection de-

pending on their CD4 count. This study investigates the most common comorbidities across pulmonary TB patients with their respective chest x-ray findings.<sup>15</sup>

Diabetes mellitus (DM) is the most prevalent comorbidity of pulmonary TB patients in SKMS Hospital. Although the precise nature of the time-regulated interaction between type 2 DM Immune dysfunctions presented in DM has been proposed to increase the risk of TB infection, which could also exacerbate its prognosis.<sup>17</sup> Uncontrolled diabetic status was associated with impairment of macrophages, which serves as a crucial immune cell for the host defense against *Mycobacterium tuberculosis* and its eradication.<sup>18–20</sup> Based on our findings, the most common radiological features of pulmonary TB-DM patients include fibro-infiltrates, Consolidation, Cavity, pleural effusion, and Tuberculoma, consistent with prior studies.<sup>21,22</sup> Radiological variations of pulmonary TB presentations in DM were highlighted by other studies reporting combinations of infiltrates, pleural effusion, fibrosis, calcifications, and pleural thickening.<sup>23,24</sup> A study conducted in China demonstrated that hyperglycemia poses a risk factor for the development of pulmonary cavity formation and lobe lesions in patients with tuberculosis and diabetes mellitus (TB-DM). Additionally, hyperglycemia was found to suppress the absolute counts of total T lymphocytes, CD8+ T lymphocytes, and natural killer (NK) cells in patients with TB-DM.<sup>17</sup>

The role of CKD in pulmonary TB involves complex interactions between compromised immune systems and physiological alterations in renal function.<sup>25</sup> The tuberculosis (TB) incidence varied according to the severity of kidney function impairment. Patients with no chronic kidney disease (CKD) or stages 1 and 2 CKD showed similar TB incidence rates, but there was a noticeable increase in incidence from stage 3a CKD onwards.<sup>25</sup> Decreased

phagocytic function and macrophage activity were also noted in CKD patients, contributing to an immunodeficient state that impairs the host response to TB infection.<sup>26</sup> Additionally, neutrophil dysfunction further compromises the ability to clear *Mycobacterium tuberculosis*.<sup>27</sup> Due to these alterations in key cellular immunity processes, CKD patients are more susceptible to latent TB infection, often pre-senting radiological features such as infiltrates, cavitations, pleural effusion, and Consolidation. These findings are consistent with a prior study that identified common pulmonary TB lesions in CKD, including infiltrates, Cavity, pleural effusion, and Consolidation.<sup>28</sup> However, the study also acknowledged the evidence of fibrosis as a radiological presentation in this condition.

The COPD comorbidity in pulmonary TB patients highlighted the complex interactions between *Mycobacterium tuberculosis* infection and pre-existing lung conditions. COPD patients typically have respiratory pathways that have undergone pathological changes, such as bronchial narrowing and increased mucus production. These disruptions can affect the body's ability to clear TB bacteria and raise the risk of TB infection. COPD often leads to decreased lung function, posing significant challenges in TB management and treatment.<sup>29–31</sup> The combination of TB symptoms and COPD can worsen patient prognosis and quality of life. TB in COPD patients can trigger a more intense systemic inflammatory response, imposing additional burdens on the cardiovascular and metabolic systems.<sup>32,33</sup> Radiological findings in TB patients with COPD typically include infiltrates, consolidations, and cavitations, with no evidence of pleural effusion or Tuberculoma. In a case report by Simamora

and Rasyidah (2020), TB patients with COPD had infiltrates, consolidations in the upper or middle regions, thick-walled cavities, and cavities surrounded by Consolidation.<sup>34</sup> A study also reported that the combination of TB and COPD could lead to lung tissue damage and enlargement of mediastinal lymph nodes as a response to infection and inflammation.<sup>35</sup>

Radiological features used to diagnose TB include infiltrates or nodules, typically observed in the upper lung fields, cavitations, calcifications, Ghon's effect, atelectasis, miliary patterns, and tuberculomas (lesions resembling coin lesions). Pulmonary TB patients with comorbidities such as DM, CKD, and COPD tend to exhibit more severe thoracic involvement compared to those without comorbidities. Overall, a more severe presentation of TB is observed in patients with severe comorbidities compared to those with newly detected comorbidities.<sup>36</sup> Although the exact pathophysiological mechanisms of these comorbidities remain unknown, some hypotheses suggest a link to cellular immune depression, alveolar macrophage dysfunction, low levels of interferon-gamma, pulmonary microangiopathy, and micronutrient deficiencies.<sup>37,38</sup> This study provides a deeper understanding of the relationship between pulmonary TB and comorbidities such as DM, CKD, and COPD. Research outcomes also reflect the diversity of chest X-ray findings in TB patients with specific comorbidities. This information can serve as the basis for developing improved management and treatment strategies for patients with pulmonary TB and comorbidities.

While this study provides valuable insights into pulmonary tuberculosis (TB) 's radiological manifestations and comorbidities, several limitations warrant consideration. Firstly, the

cross-sectional design restricts our ability to establish causality or assess temporal relationships between variables. By focusing solely on chest X-ray images obtained during the initial TB diagnosis, we may miss significant changes or developments over time, limiting the depth of our analysis. Moreover, the uneven distribution of comorbidities, particularly the preponderance of diabetes mellitus (DM), introduces potential bias and complicates the generalizability of our findings. Future studies employing longitudinal designs and ensuring a more balanced representation of comorbid conditions could provide a more comprehensive understanding of the interplay between TB and its associated health conditions.

## CONCLUSION

In conclusion, this study provides a detailed overview of the prevalence of pulmonary TB and its association with comorbidities, mainly focusing on the variations in chest X-ray imaging and the resulting lung damage. The most prevalent radiological findings in pulmonary TB patients with DM were fibroinfiltrate and Consolidation, followed by fibroinfiltrate. Among CKD patients with pulmonary TB, the radiological findings included fibroinfiltrate and Consolidation and the combination of fibroinfiltrate, Cavity, and pleural effusion. The predominant radiological findings in pulmonary TB patients with COPD were fibroinfiltrate only, followed by its combination with Consolidation. These findings provide valuable insights into the complexities of pulmonary TB in patients with comorbidities, laying the groundwork for future investigations and developing enhanced management strategies. In



upcoming research endeavors, it's recommended to adopt a Cohort-based approach. This methodology will offer a comprehensive understanding of the evolution of X-ray images throughout the treatment timeline, enabling researchers to track changes over time effectively.

Additionally, it's vital to validate X-ray findings against the patient's clinical condition and compare them with X-ray results from patients diagnosed with TB. This study identified disparities in the numbers and distribution of patients with concurrent illnesses. To ensure more consistent and accurate results in future investigations; efforts should focus on balancing the distribution among patients with comorbidities. This adjustment will provide a more precise depiction of the population under scrutiny. Furthermore, details on infiltrate distribution across the upper, middle, and lower lung regions are advised for the X-ray variable. This augmentation will deepen insights into X-ray characteristics within each lung section, thereby enhancing diagnostic accuracy and treatment efficacy.

## REFERENCES

1. Directorate General of Prevention and Disease Control. Tuberculosis Control in Indonesia 2022. Jakarta: Ministry of Health Republic of Indonesia; 2023.
2. World Health Organization. Global Tuberculosis Report 2023. Geneva: World Health Organization; 2023. Licence: CC BY-NC-SA 3.0 IGO.
3. Dinas Kesehatan Kabupaten Sidoarjo. Profil Kesehatan Kab. Sidoarjo Tahun 2019. Sidoarjo: Dinkes Kabupaten Sidoarjo; 2019. Available from URL: [www.dinkes.sidoarjo.kab.go.id](http://www.dinkes.sidoarjo.kab.go.id).
4. Cáceres G, Calderon R, Ugarte-Gil C. Tuberculosis and comorbidities: treatment challenges in patients with comorbid diabetes mellitus and depression. *Therapeutic Advances in Infectious Disease*. 2022 May;9:20499361221095831.
5. Miftahul S, Zuraidda Z, Ramadhan RM. Prevalensi Tuberkulosis Paru Pada Penderita HIV Di RSKO Jakarta Periode Januari 2016– Desember 2017. *Anakes: Jurnal Ilmiah Analisis Kesehatan*. 2019 Sep 30;5(2):152-61.
6. Lutfiana NC, van Boven JF, Masoom Zubair MA, Pena MJ, Alffenaar JW. Diabetes mellitus comorbidity in patients enrolled in tuberculosis drug efficacy trials around the world: a systematic review. *British journal of clinical pharmacology*. 2019 Jul;85(7):1407-17.
7. Hidayah H, Amal S, Rosmalinda AN. Insidensi TB Paru pada Pasien DM tipe 2 di Rumah Sakit Karya Husada Cikampek. *Pharma Xplore: Jurnal Sains dan Ilmu Farmasi*. 2021 May 5;6(1):23-31.
8. Pradhan RR, Sigdel MR. Prevalence, clinical presentation, and outcome of tuberculosis in patients with chronic kidney disease at a tertiary care hospital in Nepal. *International journal of nephrology*. 2020 1 November;2020.
9. Ruzangi J, Iwagami M, Smeeth L, Mangtani P, Nitsch D. The association between chronic kidney disease and tuberculosis; a comparative cohort study in England. *BMC nephrology*. 2020 Dec;21:1-9.
10. Vikrant S. Clinical profile of tuberculosis in patients with chronic kidney disease: A report from an endemic Country. *Saudi*

- Journal of Kidney Diseases and Transplantation. 2019 Mar 1;30(2):470-7.
11. Susilawati TN, Larasati R. A recent update of the diagnostic methods for tuberculosis and their applicability in Indonesia: a narrative review. Medical Journal of Indonesia. 2019 Oct 4;28(3):284-91.
12. Ramzi M. *Perbandingan Derajat Keparahan Gambaran X-Ray Thorax Antara Tuberkulosis Paru Tanpa Diabetes Melitus Dan Tuberkulosis Paru Dengan Diabetes Melitus* (Doctoral dissertation, Universitas Muhammadiyah Surabaya); 2020.
13. Nurmalasari R, Aprianthoro NH. Pemeriksaan Radiografi Thorax Dengan Kasus Tuberkulosis Paru. KOCENIN SERIAL KONFERENSI (E) ISSN: 2746-7112. 2020 Oct 11(1):1-3.
14. Marvellini RY, Izaak RP. Gambaran radiografi foto thorax penderita tuberkulosis pada usia produktif di RSUD Pasar Minggu (Periode Juli 2016 sampai Juli 2017). Jurnal Kedokteran Universitas Palangka Raya. 2021;9(1):1219-23.
15. Lukum E, Paramata NR, Sadjar MR. Identification of Respondent Characteristics and Relationship of Clinical Manifestations with Chest Radiograph Lesion in Pulmonary Tuberculosis Patients at Aloei Saboe Hospital. Jambura Medical and Health Science Journal. 2023 Jul 31;2(1):28-37.
16. Cuschieri S. The STROBE guidelines. Saudi journal of anaesthesia. 2019 Apr;13(Suppl 1):S31.
17. Wei R, Li P, Xue Y, Liu Y, Gong W, Zhao W. Impact of diabetes mellitus on the immunity of tuberculosis patients: a retrospective, cross-sectional study. Risk Management and Healthcare Policy. 2022 Apr 8;6:11-27.
18. Segura-Cerda CA, López-Romero W, Flores-Valdez MA. Changes in host response to mycobacterium tuberculosis infection associated with type 2 diabetes: beyond hyperglycemia. Frontiers in cellular and infection microbiology. 2019 4 October;9:342.
19. Putra ON, Hardiyono H, Rizkiyah F, NH AY. Impact of Uncontrolled HbA1C on The Outcome of Tuberculosis Treatment in TB Patients With Diabetes. Jurnal Profesi Medika: Jurnal Kedokteran dan Kesehatan. 2020 Dec 23;14(2).
20. Ferlita S, Yegiazaryan A, Noori N, Lal G, Nguyen T, To K, Venketaraman V. Type 2 diabetes mellitus and altered immune system leading to susceptibility to pathogens, especially Mycobacterium tuberculosis. Journal of clinical medicine. 2019 Dec 16;8(12):2219.
21. Dhamotharaswamy K, Selvaraj H, Lakshmanaperumal P, Sasankan AS, Thangavelu P, Thangavel S. Diabetes and TB: Confluence of Two Epidemic and Its Effect on Clinical Presentation. Current Diabetes Reviews. 2024 Jan 1;20(1):59-66.
22. Saalai KM, Mohanty A. The effect of glycemic control on clinico-radiological manifestations of pulmonary tuberculosis in patients with diabetes mellitus. The International Journal of Mycobacteriology. 2021 Jul 1;10(3):268-70.
23. Dousa KM, Hamad A, Albirair M, Al Soub H, Elzouki AN, Alwakeel MI, Thiel BA, Johnson JL. Impact of diabetes mellitus on the presentation and response to

- treatment of adults with pulmonary tuberculosis in Qatar. In Open forum infectious diseases 2019 Jan (Vol. 6, No. 1, p. ofy335). US: Oxford University Press.
24. Zhan S, Juan X, Ren T, Wang Y, Fu L, Deng G, Zhang P. Extensive radiological manifestation in patients with diabetes and pulmonary tuberculosis: A cross-sectional study. Therapeutics and clinical risk management. 2022 May 23:595-602.
25. Shu CC, Wei YF, Yeh YC, Lin HH, Chen CY, Wang PH, Cheng SL, Wang JY, Yu CJ. The impact on incident tuberculosis by kidney function impairment status: analysis of severity relationship. Respiratory research. 2020 Dec;21:1-8.
26. Syed-Ahmed M, Narayanan M. Immune dysfunction and risk of infection in chronic kidney disease. Advances in chronic kidney disease. 2019 Jan 1;26(1):8-15.
27. Gaffney E, Murphy D, Walsh A, Connolly S, Basdeo SA, Keane J, Phelan JJ. Defining the role of neutrophils in the lung during infection: Implications for tuberculosis disease. Frontiers in Immunology. 2022 20 September;13:984293.
28. Safitri DA, Mamesah YP, Timban JF. Gambaran Foto Toraks pada Pasien Tuberkulosis Paru dengan Penyakit Ginjal Kronik di RSUP Prof. Dr. RD Kandou Periode Januari-Juni 2022. Medical Scope Journal. 2022;4(1):93-8.
29. Hulya S, Naz I, Karadeniz G, Erkan S. Clinical effects of TB sequelae in patients with COPD. The International Journal of Tuberculosis and Lung Disease. 2022 Apr 1;26(4):363-8.
30. Auld SC, Kornfeld H, Maenetje P, Mlotshwa M, Chase W, Vangu MD, Torigan DA, Wallis RS, Churchyard G, Bisson GP. Pulmonary restriction predicts long-term pulmonary impairment in people with HIV and tuberculosis. BMC Pulmonary Medicine. 2021 Dec;21:1-0.
31. Fan H, Wu F, Liu J, Zeng W, Zheng S, Tian H, Li H, Yang H, Wang Z, Deng Z, Peng J. Pulmonary tuberculosis as a risk factor for chronic obstructive pulmonary disease: a systematic review and meta-analysis. Annals of translational medicine. 2021 Mar;9(5).
32. Kim DJ, Oh JY, Rhee CK, Park SJ, Shim JJ, Cho JY. Metabolic fingerprinting uncovers the distinction between the phenotypes of tuberculosis associated COPD and smoking-induced COPD. Frontiers in Medicine. 2021 14 May;8:619077.
33. Amaral EP, Vinhaes CL, Oliveira-de-Souza D, Nogueira B, Akrami KM, Andrade BB. The interplay between systemic inflammation, oxidative stress, and tissue remodeling in tuberculosis. Antioxidants & redox signaling. 2021 Feb 20;34(6):471-85.
34. Simamora RP, Rasyidah R. Laporan Kasus: Radiografi Thorax pada Pasien Tb Paru dengan Pneumothorax Spontan Sekunder. Jurnal Majority. 2020 Jul 2;9(1):141-5.
35. Kayongo A, Nyiro B, Siddharthan T, Kirenga B, Checkley W, Joloba ML, Ellner J, Salgame P. Mechanisms of lung damage in tuberculosis: implications for chronic obstructive pulmonary disease. Frontiers in Cellular and Infection Microbiology. 2023;13.
36. Kang W, Du J, Yang S, Yu J, Chen H, Liu J, Ma J, Li M, Qin J, Shu W, Zong P. The



prevalence and risks of major comorbidities among inpatients with pulmonary tuberculosis in China from a gender and age perspective: a large-scale multicenter observational study. *European Journal of Clinical Microbiology & Infectious Diseases*. 2021 Apr;40:787-800.

37. Tao NN, Li YF, Song WM, Liu JY, Zhang QY, Xu TT, Li SJ, An QQ, Liu SQ, Li HC. Risk factors for drug-resistant tuberculosis, the association between comorbidity status and drug-resistant patterns: A retrospective study of previously treated pulmonary tuberculosis in Shandong, China, during 2004–2019. *BMJ open*. 2021 Jun 1;11(6):e044349.
38. Luies L, Du Preez I. The echo of pulmonary tuberculosis: mechanisms of clinical symptoms and other disease-induced systemic complications. *Clinical microbiology reviews*. 2020 Sep 16;33(4):10-128.