

# Hasil Plagiasi Kawasaki Disease and Aneurysm of Coronary Artery in Children

*by Perpustakaan UM Surabaya*

---

**Submission date:** 07-Jul-2025 11:29AM (UTC+0700)

**Submission ID:** 2711227863

**File name:** Kawasaki\_Disease\_and\_Aneurysm\_of\_Coronary\_Artery\_in\_Children.pdf (354.01K)

**Word count:** 2300

**Character count:** 12036

## 7 Kawasaki Disease and Aneurysm of Coronary Artery in Children

Gina Noor Djalilah<sup>1\*</sup>, Muhammad Perdana Airlangga<sup>1</sup>, Irma Kartikasari<sup>1</sup>,  
Mahrus A. Rahman<sup>2</sup>, I Ketut Alit Utamayasa<sup>2</sup>, Teddy Ontoseno<sup>2</sup>

<sup>1</sup>Medical Faculty of Muhammadiyah University, Surabaya, Indonesia

<sup>2</sup>Medical Faculty of Airlangga University, Surabaya, Indonesia

### **\*) Correspondence Author**

Gina Noor Djalilah  
Faculty of Medicine  
Muhammadiyah University, Surabaya, Indonesia  
Email Address: geendjk@gmail.com, gina.noor@fk.um-surabaya.ac.id

### **Abstract**

Kawasaki infection (KD) is an intense, self-restricted vasculitis of obscure etiology that occurs predominantly in babies and small children. KD is a disease of youth, as 80% of cases happen between the ages of half a year and 5 years, with a median age of 2 to 3 years. Males are 1-6 times more likely to be influenced by KD. The ailment influences offspring of all ethnic groups, with the highest frequency occurring in offspring of Asian descent. A 3-year-old kid, with fever for 11 days before the diagnosis. Fever continues to spike. The patient got treated with anti-toxins before, yet the fever won't resolve. His eyes look red on the third day of fever. Fever followed by redness in the entire body that began from crotch to trunk, vanished in 7 days of fever, redness, enlarged in hands and feet, additionally lymph hub broadening in neck with width 1.5 cm, non-purulent, the lips was red and strawberry tongue show up in 6 days of fever and pilling skin while redness in hands and feet settled. Research facility assessment discovered an increase in leucocytes, ESR, and CRP, and a normal Electrocardiogram (ECG). Echocardiography revealed an aneurysm right coronary artery and an aneurysm of the left coronary artery. The board of patients incorporates intravenous gamma globulin, ibuprofen for therapy, echocardiography assessment, and therapy support. Long-term follow-up overseeing Kawasaki disease is the way to screen Coronary Arterial Aneurysm (CAA) complications, which are the most serious complications of KD, and are a significant reason for morbidity and mortality associated with the infection.

**Keywords:** Aneurysm, Children, Coronary artery, Kawasaki disease

## INTRODUCTION

Kawasaki infection is an intense febrile illness of youth described by clinical and histopathologic elements of foundational vasculitis.<sup>1</sup> It is a summed up fundamental vasculitis that influences veins all through the body, however, the coronary supply routes are engaged with most cases.<sup>2</sup> It has outperformed rheumatic coronary illness as the main source of acquired cardiovascular disease in children in the developed world.<sup>3,4</sup> In Indonesia, KD went to the specialist for delayed conclusion. Advani et al, in 2015, announced the primary sequential instances of KD in Indonesia at the International Kawasaki Disease Conference VIII, which was held in San Diego, USA. They detailed KD patients from 1999 to 2015 and discovered 800 cases. In Indonesia, 71% of patients in 1-2 years old, and the male to female proportion is 1.6:1 KD. It is a disease of youth, as 80% of cases happen between the ages of half a year and 5 years, with a median age of 2 to 3 years. Males are 1-6 times more likely to be influenced by KD. The illness influences offspring of all ethnic groups, with the most elevated occurrence occurring in offspring of Asian background.<sup>2</sup>

The etiology of KD remains obscure and might be attributed to the cumulative impacts of disease, susceptible reaction, and hereditary susceptibility. This multisystem vasculitis is portrayed by delayed fever, polymorphic skin rash, non-purulent conjunctival injection, focal point changes, oral mucosal changes, and cervical lymphadenopathy.<sup>3</sup> As of late, patients who are not included in the diagnosis standards of KD have increased.<sup>4</sup> With the potential for critical long-haul cardiovascular sequelae, it is basic that KD be thought of, analysed, and treated quickly. A few instances of myocardial dead tissue in youthful grown-ups have been credited to 'missed' Kawasaki disease in adolescence, which brought about coronary artery aneurysms.<sup>5</sup> Because not every patient give the full arrangement of rules and deferrals makes the progress of KD can prompt Coronary Artery Lesion (CAL), clinicians ought to likewise know about uncommon clinical and research facility discoveries of KD. Incomplete KD is more predominant in youthful babies, and a few creators propose that it is related with expanded occurrence of CAL.<sup>6,7</sup> As the main complexity, coronary conduit injuries might prompt myocardial localized necrosis, ischemic coronary illness, and sudden death. Being ready to perceive the early indications of Kawasaki disease as they happen is a significant stage in having the option to prevent a deadly coronary course aneurysm progression and increment the rate of recovery.<sup>8</sup>

The importance of this case is to know Kawasaki disease in a child, focusing on early detection of the disease, so we can minimize future complications.

## CASES

This case present a 3 years kid who went to the emergency clinic due to fever over 5 days following rash all over body, erythema and expanding in hands and feet, oral mucosal changes with erythema and breaking of lips, strawberry tongue and ensuing periungual desquamations, as of now patient sought treatment before with anti-infection agents yet not settled. No history of atopy in his family. Actual assessment showed the youngster looks sick, fever with erythema and breaking of lips, strawberry tongue, periungual desquamation. The history of redness and enlarging hands and feet previously vanished on the fifth day of fever. Given clinical, actual assessment, and history of ailment, the patient was determined to have Kawasaki Disease and a coronary blood vessel aneurysm.

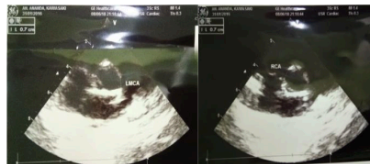

Figure 1. Aneurysm Right and Left Coronary Artery (R/LCA).

Echocardiography patients on first confirmation (figure 1) had shown aneurysm right coronary supply route (7mm) and aneurysm of left coronary conduit (7mm) with all clinical sign dominantly high fever, The patient direct intravenous gamma globulin 22 gram (~2gram/kgbw) allowed in 12 hours single portion along with ibuprofen 200 mg (80mg/kgbw/day) orally, multiple times in day.

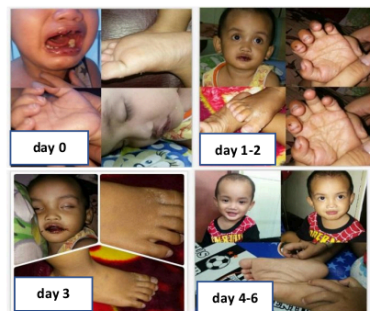

Figure 2. Clinical manifestation from day 0 admission until 6 days after treatment with IVIG (intravenous immunoglobulin) and aspirin.

Patients were not fever for 3 days following 6 days of hospitalization, ibuprofen portion declined from 200 mg (~80 mg/kg/day) four times each day to 50mg (~4mg/kg/day) every day. In follow up, his hunger is increasing, and the amount of food can last over the most recent 3 days. Research facility assessment uncovered Hb 11.5 g/dL, HCT 34.8%, erythrocytes  $4.42 \times 10^9/\mu\text{L}$ , leukocytes 6250/ $\mu\text{L}$ , platelets 326000/ $\mu\text{L}$ , ESR 113, CRP 15.5mg/dL. Following a month of illness, patient got an echocardiography assessment and was typically uncovered.

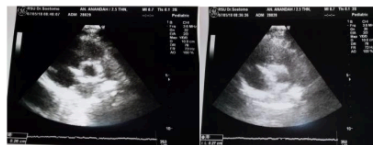


Figure 3. Echocardiography assessment: LCA (2.6mm), RCA (2.7mm)

## DISCUSSION

In this situation, the patient was determined to have Kawasaki disease and a coronary blood vessel aneurysm. Managing a kid with cardiology and disease issues requires a few methodologies, including the methodology to set up a diagnosis, the management treatment, and its complications.

The conclusion of KD depends on the clinical signs and indications because there is no symptomatic research facility test for KD. The conclusion standards for KD comprise a background marked by at least 5 days of high fever that are unresponsive to anti-infection agents and no least four of the five clinical features.<sup>1</sup> These include: (1) non-purulent conjunctivitis, (2) erythema of the oral and pharyngeal mucosa with strawberry tongue and dry broken lips without ulceration, (3) oedema as well as erythema of the hands and feet, (4) an erythematous rash and (5) cervical lymphadenopathy normally one-sided. Periungual desquamation is normal in the intense stage. Periungual desquamation of the finger and toes starts 1- multi multi-week after the beginning of the disease. These different clinical findings don't generally happen at the same time.<sup>2,4</sup>

### The management approach to Kawasaki disease

The executives contain pharmacological treatments for the treatment of KD and its complications. Beginning treatment, KD is intravenous immunoglobulin (IVIG) along with acetylsalicylic acid (ASA). Patient treated with IVIG 2 g/kg as a solitary implantation and got aspirin (ASA) 80mg/kg separated into 4 dosages per day. Patients ought to be treated with IVIG 2 g/kg as a solitary implantation,

normally given more than 10 to 12 hours, along with ASA.<sup>9-11</sup>

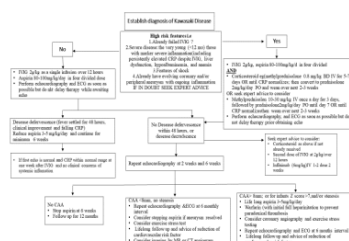


Figure 4. Recommended clinical guideline for the management of Kawasaki disease in the UK.<sup>4</sup>

When KD is analyzed, a gauge echocardiogram ought to be done, and IVIG with high-dose anti-inflammatory medicine administered. During the intense stage, ibuprofen is regulated at 80-100mg/kg/day in four isolated dosages. This high portion of headache medicine is administered until the youngest is afebrile for 2-3 days. Some clinicians proceed with a high portion of treatment until day 14 of the ailment. At the point when high-dose treatment is ceased, low-dose headache medicine treatment (3-5mg/kg/day) is started and ought to be continued until the patient shows no proof of coronary changes at 6 months after the beginning of the ailment. For youngsters who foster coronary anomalies, low-dose headache medicine might be continued indefinitely for its antiplatelet effect.<sup>10</sup>

### Dealing with the complications of Kawasaki disease

Kawasaki disease prompts coronary artery aneurysm in 25% of untreated appropriate cases. In this understanding, echocardiography was taken double cross when a patient is in a medical clinic. From first echocardiography (fourteen days of disease) showed Aneurysm Left Main Coronary Arterial with a distance across 7mm, Aneurysm Right Main Coronary Arterial with a breadth of 7mm, and Mild Tricuspid Regurgitation. From echocardiography assessment (a month of sickness), performed Left Main Coronary Artery (LMCA) had with breadth of 2.6 cm, the Right Main Coronary Artery (RCA) had with distance across of 2.7cm, and the patient arrangement for echocardiography assessment about a month and a half of the disease. Guess of aneurysms in grades 1 and 2 generally might be ideal, yet in grade 3 might foster stenosis or impediment in the future.<sup>9,10</sup>

### Follow-up plan

**Follow-up plan**  
In this persistent, CAA in the range medium measured (7mm) from about fourteen days of disease

and right now improved (2.6-2.7 mm) following a month of sickness. Most CAA arise because of KD are little to medium sizes, 50-67% of these have been displayed to relapse to typical luminal breadth inside 1-2 years of disease<sup>11</sup> by a course of limited intimal multiplication<sup>12</sup>. A 10-year follow up concentrate on examining atherosclerotic markers in KD patients with relapsed CAA found that, albeit such patients showed no stenosis or other major blood vessel irregularities, intravascular ultrasound imaging recognized different levels of intimal thickening at the destinations of relapsed CAA.<sup>11</sup>

#### CONCLUSION

Long-term monitoring overseeing Kawasaki disease is the way to screen<sup>1</sup> Coronary Arterial Aneurysm (CAA) difficulties, which are the most serious complications of KD, and are the significant reason for morbidity and mortality associated with the infection. The Importance of KD is the early identification of an aneurysm of the coronary artery by echocardiography.

#### CONFLICT OF INTEREST

All co-authors have seen and agree with the contents of the manuscript and there is no conflict of interest to report.

#### REFERENCES

1. Greco A, Virgilio A, Rizzo MI, Tombolini M, Gallo A, Fusconi M, et al. Review Kawasaki disease: An Evolving paradigm. Autoimmunity review. 2015;14: 703-9.
2. Uehara R, Yashiro M, Nakamura Y, Yanagawa H. Parents with a history of Kawasaki disease whose child also had the same disease. Pediatrics International. 2011;53:511-4.
3. McCrindle BW, Rowley A, Newburger J, Burns J, Bolger AF, Gewitz M, et al. Diagnosis, treatment, and long-term management of Kawasaki disease. Circulation. 2017;135:927-99.
4. Eleftheriou D, Levin M, Shingadia D, Tulloh R, Klein NJ, Brogan PA. Management of Kawasaki disease. Arch Dis Child. 2014;99:74-83.
5. Rowley AH, Shulman ST. Editorial commentary: missing the forest for the trees: respiratory viral assays in patients with Kawasaki disease. Clin Infect Dis. 2013;56:65-6.
6. Burns JC, Franco A. The immunomodulatory effects of intravenous immunoglobulin therapy in Kawasaki disease. Expert Rev Clin Immunol. 2015;11:819-25.
7. Kobayashi T, Kobayashi T, Morikawa A, Ikeda K, Seki M, Shimoyama S, et al. Efficacy of intravenous immunoglobulin combined with prednisolone following resistance to initial intravenous immunoglobulin treatment of acute Kawasaki disease. The Journal of Pediatrics. 2013;163:521-6.
8. Lee SB, Choi HS, Son S. Cardiac Function in Kawasaki Disease Patients with Respiratory Symptoms. Korean circulation journal. 2015;45:317-24.
9. Kitano N, Suzuki H, Takeuchi T. Epidemiologic features and prognostic factors of coronary artery lesions associated with Kawasaki disease based on a 13-year cohort of consecutive cases identified by complete enumeration surveys in Wakayama, Japan. Journal of epidemiology / Japan Epidemiological Association. 2014;24:427-34.
10. Lega JC, Bozio A, Cimaz R, Veyrier M, Floret D, Ducreux C, et al. Extracoronary echocardiographic findings as predictors of coronary artery lesions in the initial phase of Kawasaki disease. Arch Dis Child. 2013;98:97-102.
11. Kocabaş BA, Karbuz A, Karadeniz C, Çiftçi O, Özdemir H, Bolkent M, et al. Another face of Kawasaki disease. The Turkish Journal of Pediatrics. 2014; 56: 392-8.
12. Kang J, Hong S, Seo IA, Kwak MH, Cho S, Kim D, et al. Early Detection of Kawasaki Disease in Infants. Korean Circulation Journal. 2015; 10: 510-5.

# Hasil Plagiasi Kawasaki Disease and Aneurysm of Coronary Artery in Children

## ORIGINALITY REPORT

12%

SIMILARITY INDEX

7%

INTERNET SOURCES

9%

PUBLICATIONS

6%

STUDENT PAPERS

## PRIMARY SOURCES

- |          |  |    |
|----------|--|----|
| <b>1</b> | Cedric Manlhiot, Elizabeth Niedra, Brian W. McCrindle. "Long-term Management of Kawasaki Disease: Implications for the Adult Patient", Pediatrics & Neonatology, 2013<br><small>Publication</small>  | 3% |
| <hr/>    |  |    |
| <b>2</b> | circ.ahajournals.org<br><small>Internet Source</small>   | 2% |
| <hr/>    |  |    |
| <b>3</b> | Submitted to William Carey University<br><small>Student Paper</small>  | 2% |
| <hr/>    |  |    |
| <b>4</b> | jurnalnasional.ump.ac.id<br><small>Internet Source</small>   | 1% |
| <hr/>    |  |    |
| <b>5</b> | www.cambridge.org<br><small>Internet Source</small>  | 1% |
| <hr/>    |  |    |
| <b>6</b> | Submitted to University of Newcastle<br><small>Student Paper</small>   | 1% |
| <hr/>    |  |    |
| <b>7</b> | Brian W. McCrindle, Anne H. Rowley, Jane W. Newburger, Jane C. Burns et al. "Diagnosis, Treatment, and Long-Term Management of Kawasaki Disease: A Scientific Statement for Health Professionals From the American Heart Association", Circulation, 2017<br><small>Publication</small> | 1% |

Exclude quotes ☐ On

Exclude matches ☐ < 20 words

Exclude bibliography ☐ On