

# HISTOPATHOLOGICAL DESCRIPTION OF THE LUNGS OF MICE (MUSMUSCULUS) THAT WAS GIVEN ASCORBIC ACID

*by Dita Artanti Dosen Fik*

---

**Submission date:** 27-Dec-2021 02:08PM (UTC+0700)

**Submission ID:** 1735850724

**File name:** F\_THE\_LUNGS\_OF\_MICE\_MUSMUSCULUS\_THAT\_WAS\_GIVEN\_ASCORBIC\_ACID.pdf (322.88K)

**Word count:** 1883

**Character count:** 12508

HISTOPATHOLOGICAL DESCRIPTION OF THE LUNGS OF MICE  
(MUS MUSCULUS) THAT WAS GIVEN ASCORBIC ACID

---

Yeti Eka Sispta Sari<sup>1(CA)</sup>, Dita Artanti<sup>2</sup>, Fitrotin Azizah<sup>3</sup>, BATERUN KUNSAH<sup>4</sup>  
<sup>1(CA)</sup>D3 TLM, Faculty of Health Sciences, University Muhammadiyah Surabaya;  
[yetiekasispta@gmail.com](mailto:yetiekasispta@gmail.com) (Corresponding Author)

<sup>2</sup>D3 TLM, Faculty of Health Sciences, University Muhammadiyah Surabaya; [ditaarta3009@gmail.com](mailto:ditaarta3009@gmail.com)

<sup>3</sup>D3 TLM, Faculty of Health Sciences, University Muhammadiyah Surabaya; [ichafitrotin@gmail.com](mailto:ichafitrotin@gmail.com)

<sup>4</sup>D3 TLM, Faculty of Health Sciences, University Muhammadiyah Surabaya; [kunsa11980@gmail.com](mailto:kunsa11980@gmail.com)

---

ABSTRACT

Ascorbic acid or better known strengthening immunity against infection, especially during the current covid 19 outbreak, the people's consumption power of ascorbic acid is extraordinary. The lung is an elastic cone-shaped organ located in the thoracic cavity and is an organ that often experiences pathological abnormalities. An imbalance of oxidants- antioxidants are mutually reinforcing and contribute to tissue damage. The purpose of this study was to determine the effect of consuming low doses of ascorbic acid every day on lung histopathology, especially fibrosis in mice (Mus musculus). This study was an experimental study with post-test only with a control design and used 15 mice as samples. Samples were divided into 5 groups consisting of one positive control group, one negative control group and three different dose groups from the ascorbic acid treatment group (0,76mg, 0,51 mg dan 0,26 mg in one treatment, here is done 2 times the treatment in one day for 7 days). Data analysis matches results to the score table determining the damage in the form of fibrosis. The histological structure of the lungs of mice from each treatment compared to the control. The damage score of each treatment then per group is summed up and averaged. Furthermore, data analysis is carried out using the One Way ANOVA test. In conclusion, study was conducted consumption of ascorbic acid below the dose also resulted in damage to the pulmonary organs and the result is the same as not consuming ascorbic acid.

**Keywords:** lung fibrosis, Ascorbic acid, Mus Musculus.

---

INTRODUCTION

Consumption of ascorbic acid during a pandemic is like daily food consumption due to excessive fear of covid 19. So far, vitamin C or ascorbic acid is known for its role in maintaining and strengthening immunity against infection. The main forms of ascorbic acid eaten are L-ascorbic and dehydroascorbic acid. Synthetic ascorbic acid is available in a variety of supplements in various forms, both in the form of tablets, capsules, chewable tablets, crystalline powder, and in the form of a solution. Vitamin C is called an antioxidant because by donating electrons it prevents other substances in the composition from being oxidized, an imbalance of oxidants - antioxidants are mutually reinforcing and play a role in causing tissue damage (Kumar et al., 2007).

Lung is an elastic, cone-shaped organ located in the thoracic cavity and is an organ that often experiences pathological abnormalities. In the distal respiratory system, such as the alveoli, defense against microbes no longer depends on ciliated epithelium, goblet cells, and mucus but on protective cells in lung tissue, namely lymphocytes and plasma cells that produce antibodies, macrophages, and polymorphonuclear lymphocytes that produce antibodies. phagocytes (Barret et al., 2010). Severe alveolar epithelial damage causes difficulties in the repair mechanism of the lung and leads to fibrosis. This lung injury is also caused by an imbalance of pro-inflammatory and anti-inflammatory cytokines

METHODS

Prepared a number of 15 mice with details of 5 treatments with 3 repetitions, total 20 and we add 5 to spare assuming each treatment has a reserve of 1 mouse. The mice used were mice aged 1-2 months because at this age they were in a period of good development.

	Mice 20g	Rat 200g	Rabbit 1,5kg	Human 70kg
Mice 20g	1,0	7,0	27,80	387,9
Rat 200g	0,14	1	3,9	56,0
Rabbit 1,5kg	0,04	0,25	1,0	14,2
Human 70kg	0,0026	0,018	0,07	1,0

Table 1. Experimental animal dose conversion

Dosage cytostatics calculation is done with the formula:

Dosage = LPT X COMMON DOSE

$$LPT = \frac{\sqrt{\text{Height} \times \text{Weight}}}{3600}$$

Height Mice = 17 cm

Weight Mice = 24 gr

Ascorbic Acid Dosage per day

1 capsule = 50 mg, recommended dose 1 x 3 (1 capsule taken 3 times a day) = 50 x 3 = 150 mg

$$LPT = \frac{\sqrt{17 \times 24}}{3600} = 0,11 \times 150 = 16,5 \text{ mg}$$

The usual dose of ascorbic acid consumption in mice is 16.5 mg per day. Then do the labeling of the cage. One cage contained 3 mice, namely cages coded 1, 2, 3, 4 and 5 the treatment code was P (1) Positive control treatment: mice were given standard feed, water and given 16,5 mg Vit.C, P (2) Negative control treatment: mice were given standard feed and water, P(3) Food treatment + 0.76 mg Vit.C dissolved in 0.24 ml sterile pz, P(4) food + 0.51 mg Vit.C dissolved in 0.49 ml sterile pz, P(5) Treatment food + 0.26 mg Vit. C dissolved in 0.74 ml sterile pz., Each treatment was given 2 times in one day, in the morning at 08.00 am and in the afternoon at 15.00 pm. To facilitate the sonde process, vitamin C is diluted using sterile distilled water to a volume of 1 ml. The study was conducted using a completely randomized design (CRD) with three repetitions. Total dose of ascorbic acid given to mice every day was P1:16.5mg, P3:1.52mg, P4: 1.02mg, P5:0.52mg.

Rate of Change	Information	Scores
Normally	There is no histological structure.	0
Mild	Damage less than a third of the entire field of view	1
Moderate	Damage of one-third to two-thirds of the entire field of view	2
Severe	Damage to more than two-thirds of the entire field of view	3

Table 2. Lung histopathological damage assessment score (Hansel & Barnes 2004)

The treated and untreated mice were put into jars that had been given chloroform to be anesthetized before surgery. After the operation the container contains a 10% formalin solution for the fixation process. Preparation of preparations in this study was carried out by paraffin method, Hematoxylin Eosin (H&E) staining. The working stages of the paraffin method are as follows: fixation, dehydration, clearing, infiltration, embedding, sectioning, affixing, deparaffinization, staining, mounting, and labeling. Observations were made using a light microscope with a magnification of 400x across the entire field of view. The assessment of the degree of lung damage is done qualitatively based on the damage score (Table 2) by determining the damage in the form of necrosis, congestion, bleeding, inflammatory cells, erosion of

the bronchial, thickening of the walls of the septa alveoli, narrowing, widening of alveoli, phyrin, oedemafluid, and granulomas. The histological structure of the lungs mice from each treatment compared to the control. The damage score of each tweet then per group is summed up and averaged. Furthermore, dataanalysis carriedoutusingtheOneWayANOVAtest..

### RESULTS

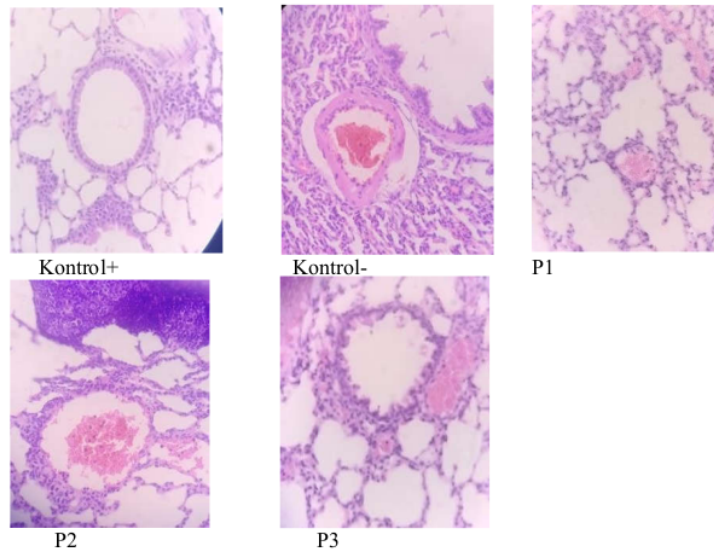


Figure 1. Histopathological appearance of pulmonary fibrosis of mice (*Mus musculus*) after ascorbic acid probe for 7 days (HE staining, 400x objective magnification).

Giving ascorbic acid for by sondemethod provides a change in the histopathological picture of the micelung (*Mus musculus*). In the control group (K+)/ P1, there has been no change in the histopathological picture of the lungs. The alveolaris and alveolus ducts are wrapped by finely shaped alveolus cells, in the proprialamina that circle from the edge of the alveolus there is webbing of smooth muscle cells. In the control group (K-)/P2 there was a presence of bleeding and in the treatment of P3, P4, P5 there is inflammatory cell powder and scarring and hemorrhagic tissue scattered in the lung area.

Group Treatment	Repetition 1	Repetition 2	Repetition 3
Control +(P1)	0	0	0
Control -(P2)	1	1	0
Treatment 3:0,76	1	1	1
Treatment 4:0,51	1	1	1
Treatment 5:0,26	1	1	1
Total	4	4	3
SD	0,8	0,8	0,6

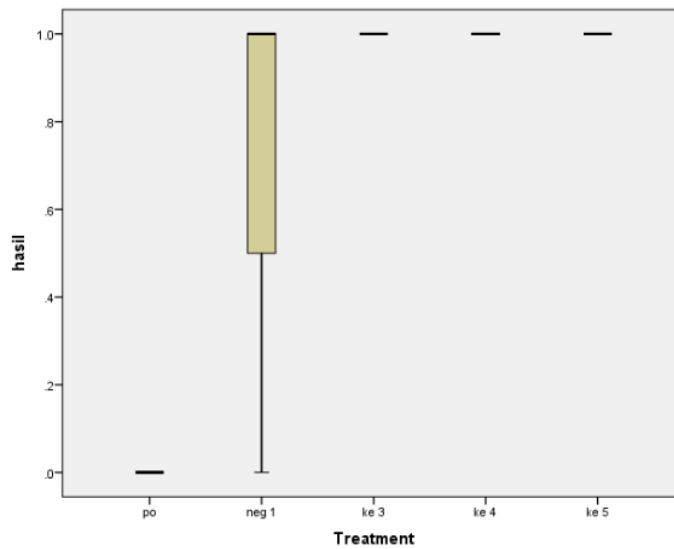
Table 3. Scoring resultson 5 treatments with 3 repetitions of ascorbic acid

In table 3 it appears not much different between the treatment 3, 4 and 5 but when compared to positipcontrol given ascorbic acid according to the recommended dose the results are very different. In positipcontrol there is a good picture of cells in the absence of fibrosis. Pulmonary fibrosis is caused by scar tissue forming inside the lungs. There are several factors that can trigger the formation of scar tissue.

**Tests of Normality<sup>a,c,d,e</sup>**

Treatment	Kolmogorov-Smirnov <sup>b</sup>			Shapiro-Wilk		
	Statistic	df	Sig.	Statistic	df	Sig.
hasil neg 1	.385	3	.	.750	3	.000

- a. Result is constant when Treatment = po. <sup>1</sup> It has been omitted.
- b. Lilliefors Significance Correction
- c. Result is constant when Treatment = ke 3. It has been omitted.
- d. Result is constant when Treatment = ke 4. It has been omitted.
- e. Result is constant when Treatment = ke 5. It has been omitted.



**Test of Homogeneity of Variances**

hasil	Levene Statistic	df1	df2	Sig.
	16.000	4	10	.000

**ANOVA**

hasil	Sum of Squares	df	Mean Square	F	Sig.
Between Groups	2.267	4	.567	8.500	.003
Within Groups	.667	10	.067		
Total	2.933	14			

**DISCUSSION**

The results of this study there is an influence of given ascorbic acid below the prescribed dose, in the treatment of I or control positipmusmusculus given ascorbic acid as recommended in one day adjusted

to the tamping power of the stomach, food is reduced and ascorbic acid is included according to the dose obtained results of no changes in tissues. In treatment 2 or negative control is given food only as usual without any intake of ascorbic acid obtained the result of minor damage to the tissues. In the treatment of food treatment + 0.76 mg Vit. C dissolved in 0.24 ml p/z sterile obtained the presence of minor damage, as well as in treatment 4 and 5 found damage with a degree of minor damage, P(4) food + 0.51 mg Vit. C dissolved in 0.49 ml p/z sterile, P(5) Food treatment + 0.26 mg Vit. C dissolved in 0.74 ml p/z sterile. Based on the results of the study showed that the consumption of vitamin C or ascorbic acid at low doses can damage the lungs, in other words there is no difference with the control or without the consumption of ascorbic acid. please note, consumption of ascorbic acid must pay attention to the rules or recommended dosages and do not arbitrarily consume outside the recommended dose because the physiological conditions shown in the treatment in mice do not show good conditions in the lungs.

#### CONCLUSION

Of the many cases of cytokine storms that occur due to the consumption of ascorbic acid that exceed the dose turned out in the pandemic when this study was conducted consumption of ascorbic acid below the dose also resulted in damage to the pulmonary organs and the result is the same as not consuming ascorbic acid. To get the maximum benefit of ascorbic acid then you must comply with the recommendations of a predetermined dose, do not make your own rules by reducing or increasing the dose of consumption without any instructions from a doctor or pharmacist, because it will cause adverse effects on your lungs.

It can be concluded with insignificant results should be the time the study is added

#### REFERENCES

- AbdulRohim, Alimuddin, Erwin, ANALISIS KANDUNGAN ASAM ASKORBAT DALAM BUAH NAGA MERAH (*Hylocereus Polyrhizus*) DENGAN IODIMETRI. Analisa Kandungan. Kimia FMIPA Unmul
- Altika, S., & Wijayanti, I. T. (n.d.). ANALISIS STATUS ASAM ASKORBAT, NILAI LIMFOSIT DAN LAMAPENGobatan PASIEN TB MDR1 RSUD SOEWONDO PATI (Vol. 8).
- Bancroft's (2013). THEORY and PRACTICE of HISTOLOGICAL TECHNIQUES. seventh edition. Churchill Livingstone. ELSEVIER. UK
- Coleman, B. D., & Fuoss, R. M. (1955). Quaternization Kinetics. I. Some Pyridine Derivatives in Tetramethylene Sulfone. *Journal of the American Chemical Society*, 77(21), 5472–5476. <https://doi.org/10.1021/ja01626a006>
- Erick Kristian, Dewi Indrawati. (2017) Buku Ajar TLM. SITO HISTOTEKNOLOGI. KEMENKES
- Hansel T. T., Barnes P. J. 2004. An Atlas of Chronic Obstructive Pulmonary Disease. London : Parthenon Publishing
- Harulal- Rasyid, Subeki, Wisnu Satyajayadan Agus Saptomi, KAJIAN PENGGUNAAN ASAM ASKORBAT UNTUK FORTIFIKASI BERASSIGER. ISSN 2088–5369. *Jurnal AGROINDUSTRI*. epository.lppm.unila.ac.id/7254/1/3834-7086-1-PB.pdf
- Junqueira, Carneiri, Kelley (1998). HISTOLOGIDASAR. Edisi 8. EGC. Jakarta.
- Monica, M., Adi, A. A. A. M., & Winaya, I. B. O. (2019). Histopatologi Bronkiolus dan Pembuluh Darah Paru Mencit Jantan Pasca Terpapar Asap Rokok Elektrik. *Buletin Veteriner Udayana*, 157. <https://doi.org/10.24843/bulvet.2019.v11.i02.p08>

- Roselyn, A. P., Widiastuti, E. L., Susanto, G. N., & S. (2017). Pengaruh Pemberian Taurin terhadap Gambaran Histopatologi Paru Mencit (*Mus musculus*) yang Diinduksi Karsinogen Benzo(a)piren secara In Vivo. *Jurnal Natur Indonesia*, 17(1), 22. <https://doi.org/10.31258/jnat.17.1.22-32>
- Rohi Bire, I., Bagus Oka Winaya, I., & Agung Ayu Mirah Adi, A. (n.d.). Perubahan Histopatologi Hati dan Paru Mencit Pasca Induksi dengan Zat Karsinogenik Benzo(a)piren (HISTOPATHOLOGICAL CHANGES OF MICE LIVER AND LUNG POST INDUCTION WITH CARCINOGENIC SUBSTANCES BENZO(A)PYRENE). <https://doi.org/10.19087/imv.2018.7.6.634>
- Rondius Solfaine, Olan Rahayu Puji Astuti Mussa, Apriska Ayuningtias, Dyah Widhowati, GAMBARAN HISTOPATOLOGI PARU PADA MENCIT (*Mus musculus*) YANG DIPAPARAS APROKOKKRETEKAKIBATPENGARUHPEMBERIANINFUSATEHHIJAU (Camellia sinensis). e-ISSN 2685-8894; p-ISSN 2460-9773. *Jurnal Vitek Bidang Kedokteran Hewan* Vol.10, November 2020
- Terena Chintya Mardia Utama 22010112110110\_Lap.KTI\_Bab2.(n.d.).
- Sartika, N. A., Winaya, I. B. O., Adi, A. A. A. M., & Putra, I. P. W. J. (2018). Perubahan Histopatologi Paru-paru Mencit Jantan Pascapaparan Asap Rokok Elektrik. *Indonesia Medicus Veterinus*, 402. <https://doi.org/10.19087/imv.2018.7.4.402>
- Wiradi, A., Fidiawati, W. A., & Munir, S. M. (n.d.). Gambaran Histopatologi Paru Mencit (*Mus musculus*) Setelah Pemaparan Paraquat..
- Winda Trisna Wulandari, ANALISIS KANDUNGAN SAMPAK KORBATDALAM MINUMAN KEMASAN YANG MENGANDUNG VITAMIN C. *Jurnal Kesehatan Bakti Tunas Husada* Volume 17 Nomor 1 Februari 2017





# HISTOPATHOLOGICAL DESCRIPTION OF THE LUNGS OF MICE (MUSMUSCULUS) THAT WAS GIVEN ASCORBIC ACID

---

## ORIGINALITY REPORT

---

3%

SIMILARITY INDEX

%

INTERNET SOURCES

1%

PUBLICATIONS

2%

STUDENT PAPERS

---

## PRIMARY SOURCES

---

1

Submitted to Grand Canyon University

Student Paper

2%

---

2

Shlomo Fastig, Omer Porat, Abraham Englander, Detlev Sprung, Karin U. Stein, Erik Sucher. "Lidar for Wind and Optical Turbulence Profiling", EPJ Web of Conferences, 2018

Publication

1%

---

Exclude quotes On

Exclude matches < 20 words

Exclude bibliography On