

Pendekatan Klinis Hipoglikemia Berulang pada Pasien dengan Karsinoma Sel Hati: Laporan Kasus dan Tinjauan Kepustakaan

by Admin Sdm Jafa Fk Admin Fk

Submission date: 19-Jul-2024 02:42PM (UTC+0700)

Submission ID: 2419090342

File name: Hepatocellular_Carcinoma_A_Case_Study_and_Literature_Review.pdf (618.05K)

Word count: 4365

Character count: 25165

**Pendekatan Klinis Hipoglikemia Berulang pada Pasien dengan Karsinoma Sel Hati:
Laporan Kasus dan Tinjauan Kepustakaan**

**Approach to Refractory Hypoglycemia in a Patient with Hepatocellular Carcinoma:
A Case Study and Literature Review**

Audy Meutia Ariana^{1*)}, Ganjar Adityo Permadi², Hermawan Susanto²

¹Department of Internal Medicine, Faculty of Medicine, Universitas Muhammadiyah Surabaya, Indonesia

²Division of Endocrinology and Metabolic Disease, Department of Internal Medicine, Faculty of Medicine, Universitas Airlangga –
dr. Soetomo Hospital, Surabaya, Indonesia

Article Info

Article History:

Received: January 24, 2024

Accepted: February 26, 2024

Published: February 29, 2024

*)Corresponding author:

E-mail: audymeutiaariana@um-surabaya.ac.id

How to cite this article:

Ariana, A.M., Permadi, G.A., Susanto, H. (2024). Approach to Refractory Hypoglycemia in a Patient with Hepatocellular Carcinoma: A Case Study and Literature Review. *Journal of Agromedicine and Medical Sciences*. 10(1), 5-11

<https://doi.org/10.19184/ams.v10i1.45924>

Abstrak

Kejadian hipoglikemia pada pasien non-diabetes merupakan temuan yang cukup jarang. Etiologi hipoglikemia yang tidak terkait penyakit diabetes cukup bervariasi, antara lain hiperinsulinemia, defisiensi hormon, keganasan, hingga penyakit kritis. Laporan kasus ini menggambarkan upaya penegakan penyebab hipoglikemia berulang pada seorang pasien laki-laki usia 46 tahun yang sebelumnya telah didiagnosis dengan karsinoma sel hati (KSH). Anamnesis dan pemeriksaan yang telah dilakukan berhasil mengerucutkan diagnosis diferensial penyebab hipoglikemia menjadi antara gagal hati akibat KSH atau akibat sindrom paraneoplastik dari tumor sel non-beta yang dikenal dengan istilah non-islet cell tumor hypoglycaemia (NICTH). Ketiadaan stigmata penyakit liver kronis pada pasien mendukung NICTH sebagai penyebab utamanya. Pada akhirnya, keputusan pemeriksaan diagnostik yang sebaiknya dilakukan dalam menghadapi kasus langka seperti NICTH bergantung pada penilaian klinis dengan mempertimbangkan asas efektivitas biaya dan juga harapan pasien. Terlepas dari apapun etiologinya, manajemen hipoglikemia harus dilakukan sesegera mungkin. Dalam kasus ini, pilihannya dapat berupa terapi medikamentosa atau terapi definitif seperti pembedahan.

Kata Kunci: Hipoglikemia, NICTH, karsinoma sel hati

Abstract

Symptomatic hypoglycemia in patients without underlying diabetes is uncommon. Etiology of non-diabetic hypoglycemia varies from hyperinsulinism, hormone deficiencies, malignancies, to critical illness. This case report illustrates the attempt to determine the cause of refractory hypoglycaemia in a 46 years old male patient with underlying hepatocellular carcinoma (HCC). Anamnesis and examinations have narrowed differential diagnosis to concurrent systemic illness (liver failure due to HCC) or paraneoplastic syndrome from non-beta cell tumors, referred as non-islet cell tumor hypoglycemia (NICTH). It was noted that the absence of chronic liver disease stigmata has put NICTH as the possible main cause. Deciding what diagnostic modalities needed to perform to establish the diagnosis eventually relies on clinical judgement while taking cost-effectiveness and patients' preference in consideration, particularly in low-resource settings. Nonetheless, the main goal of treating hypoglycemia is to immediately achieve and sustain euglycemia which can be achieved conservatively or definitively with surgery despite the etiology.

Keywords: Hepatocellular carcinoma, Hypoglycemia, NICTH.



Introduction

Hypoglycemia is a condition characterized by low plasma glucose concentrations which may progress to severe complications, such as lethal neurologic or cardiovascular ischemia, when not being treated immediately. Symptomatic hypoglycemia in patients without underlying diabetes is uncommon because counter-regulatory mechanism in the human body exists to compensate for low glucose level. Most cases result as complications from diabetes mellitus medication. Etiology of non-diabetic hypoglycemia varies from hyperinsulinism, hormone deficiencies, malignancies, to critical illness (Martens and Tits, 2014). Nonetheless, establishing the true cause may be difficult particularly in low-resource settings due to the fact that the diagnostic modalities required are mostly advanced and unavailable. Consequently, diagnosis is often made through exclusions.

Hypoglycemia in hepatocellular carcinoma (HCC) is not unusual given that decompensated liver may naturally impair gluconeogenesis pathway. Tumor-induced hypoglycemia which mechanism involves tumor's ability to directly produce insulin growth factor may also be a possible cause albeit rare. Tumor associated hypoglycemia may be caused by insulin producing islet-cell tumors (i.e. insulinoma) or a manifestation of paraneoplastic syndromes from extra-pancreatic tumors which include HCC (Pelosof and Gerber, 2010; Regino et al., 2020). This case report illustrates the attempt to determine the cause of refractory hypoglycemia in a patient with HCC.

Case Report

We report a 46 years old male patient admitted to a tertiary hospital in Surabaya, Indonesia, with refractory hypoglycemia referred from a hospital in Bojonegoro district, located 68 miles from Surabaya city. He was found unconscious in his bed when his family tried to wake him up in the morning, therefore, the true duration of patient's blackout is not clearly known. The examination done in the Bojonegoro hospital showed normal vital signs and rapid glucose test showed 0 mg/dL. The patient was immediately treated with intravenous glucose injection and maintained with 5% dextrose solution. Five months ago, he started to feel an enlarged stomach particularly

on the upper right part that felt solid and grew progressively. It was the first time he seeks for medication and was eventually diagnosed by an internist with liver cancer and hepatitis B after several examinations including abdomen ultrasonography (USG) and computed tomography (CT) scan. The patient refused treatment because he was told that he had to be referred across the city for advanced therapy. He accepted his condition as a terminal state and only consumed curcuma occasionally. Two weeks before admission, the patient frequently complained of weakness and tremulousness that resolved after he ate something. This was his first blackout episode. During observation in the emergency room in Bojonegoro, he experienced loss of consciousness recurrently with a glucose level below 50 mg/dL and became responsive each time 40% dextrose concentrated solution was injected. This incidence occurred repeatedly that it was decided to refer him to Surabaya.

The physical examination in Surabaya showed weak state and GCS 4/5. Blood pressure 130/90 mmHg, heart rate 110 bpm regular, respiratory rate 22 times/minutes, temperature of axilla 36,2°C, capillary refill time less than 2 seconds, oxygen saturation 97% without oxygen support (98-99% with nasal cannula 4 liters/minute). From physical examination, a mass in right hypochondriac region reaching the epigastric region was palpable (**Figure 1**). Chronic liver disease stigmata such as spider angioma, jaundice, palmar erythema, gynecomastia, and ascites were not found. The laboratory result is shown in **Table 1**. Thorax photo discovered normal lungs and heart with no signs of metastatic in lungs and bones. The patient brought abdominal USG 4 months prior to current admission. The USG showed enlarged left lobe with solid and bobbing mass 68,2 x 69,3 mm and multiple solid nodule in its surrounding. The CT scan done in Surabaya exhibited enlarged liver size with heterogeneous parenchyma density; solid mass in right lobe 7,9 x 14,2 cm and solid mass in left lobe 16,4 x 22,4 cm with positive infiltration; normal biliary duct; and thickening of right and left pleura. It suggested hepatocellular carcinoma on right and left lobes with no thrombus portal and minimal bilateral pleural effusion (**Figure 2**).

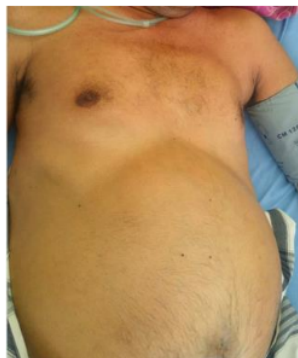

Figure 1. Physical examination exhibiting abdominal distension without chronic liver disease stigmata

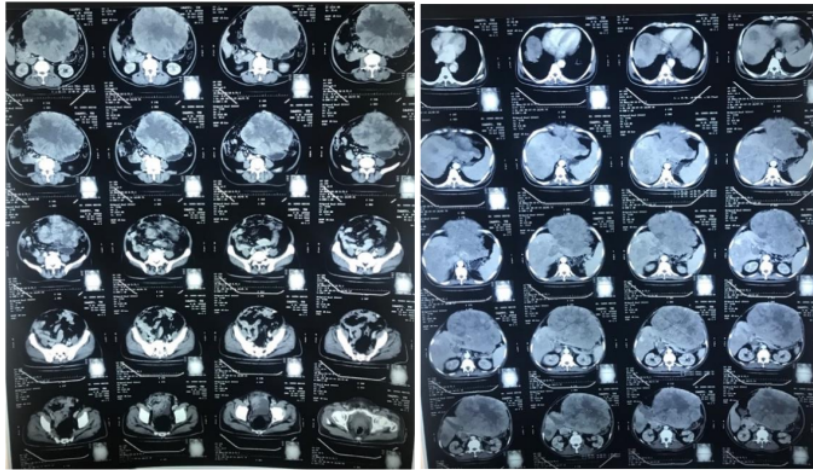


Figure 1. Abdominal CT-Scan suggesting hepatocellular carcinoma

Table 1. Laboratory data progress

	Normal reference	Past examinations (4 months prior to admission)	Day 1 admission	Day 3 admission
Hgb (g/dL)	13.3-16.6		10.5	10.6
WBC (/ μ L)	3.37-10.0 x10 ³		9.65	12.730
Plt (/ μ L)	150-450,000		272,000	191,000
Neut (%)			91.6	86.8
Lymph (%)			2.5	
MCV (fl)	86.7-102.3		86.1	
MCH (pg)	27.1-32.4		27	
MCHC (gr/dl)	29.7-33.1		29.2	
Glucose (mg/dL)	<100		<5	
BUN (mg/dL)	10-20		17	
Creatinine (mg/dL)	0.5-1.2		0.6	
SGOT (U/L)	<41		1,420	
22 T (U/L)	0-50		464	
Albumin (g/dL)	3.4-5.0		3.8	
Total protein (g/dl)	6.0-8.3	6		
30 bulin (g/dl)	2.0-3.5	2.6		
Total bilirubin (mg/dL)	0.2-1.0		5.54	
Direct bilirubin (mg/dL)	<0.2		4.03	
PPT	9-12		13.4	
AP T	23-33		27.5	
21 Ca (mmol/L)	136-144		142	
K (mmol/L)	3.8-5.0		4.2	
Cl (mmol/L)	97-103		99	
AFP (ng/ml)	<20	>400		
HbsAg	Negative	Reactive		
Anti-HCV	Negative	Non-reactive		
HIV	Negative	Negative		
HbA1c (%)	<5.7	5.5		
Insulin (μ U/mL)	3,2-28,5			1,9
Urine			SG 1,020 pH 6 Glucose (-) Ketone (-) Bil (+3) Pro (+2) Nitrite (+) Uro (+2) Leu (+1) Bacteria (+)	

The patient was diagnosed with hepatocellular carcinoma (Child-Pugh A), urinary tract infection, and refractory hypoglycemia. He was planned to have blood and urinary culture, insulin measurement, and strict glucose monitoring every 3 hours. The absence of chronic liver disease stigmata and sepsis signs as well as the newly found low insulin result suggested NICTH as a possible etiology. Nonetheless, due to limited resource and patient's wish for a palliative care, further diagnostic method including pathological examination was not conducted.

The patient was provided with diet through nasogastric tube and was treated with the following medications: infusion of 5% dextrose 1000 mL/day, intravenous injection of ceftriaxone 1 gram/12 hours, intravenous injection of methylprednisolone 62.5 mg/day, lamivudine 100 mg/day, and additional intravenous injection of 40% dextrose following every documented hypoglycemia. Despite being provided with enteral nutrition in a timely manner and treated with steroid injection, the blood glucose level still fluctuated from 32 mg/dl to 123 mg/dl accompanied with frequent loss of consciousness. On the third day of treatment, patient refused further treatment and asked to be discharged despite of the poor condition because he preferred palliative and supportive care at home. He was discharged with nasogastric tube to support his diet needs at home, methylprednisolone 16 mg/8 hours orally, cefixime 100 mg/12 hours orally, and lamivudine orally. The patient passed away five days after discharge in his home.

Discussion

Global data suggest HCC as the fifth most prevalent cancer worldwide with high mortality. The main risk factors of HCC include hepatitis B virus (HBV), hepatitis C virus, alcohol, nonalcoholic fatty liver disease, and metabolic syndromes (McGlynn et al., 2021). Hepatitis B may progress to HCC through integration of HBV-DNA to the host genome stimulating carcinogenic process which involves chromosome alterations,

p53 inactivation, and overexpression of β 16 progenitor cells (Levrero and Zucman-Rossi, 2016). The incidence of hypoglycemia in HCC is not clearly known.

Hypoglycemia is a condition of which manifestations of Whipple's triad are documented: symptoms or signs consistent with hypoglycemia; low glucose level concentration (less than 55 mg/dl or 3,0 mmol/liter); and resolution of symptoms after glucose level is raised. Potential etiology of hypoglycemia in non-diabetic patient can be simply classified as drug-induced, concurrent systemic illness, hormone deficiency, and hyperinsulinemia (Figure 3) (Martens and Tits, 2014; Bansal and Weinstock, 2020). It is important to briefly exclude the possibility of each of the etiologies.

Drug-induced hypoglycemia can be excluded given that patient did not take any medications that may precipitate hypoglycemia such as insulin, insulin secretagogues, alcohol, fluoroquinolones, sulfonamides, ACE-inhibitors, and herbal drugs (Bansal and Weinstock, 2020). Counter-regulatory hormones consisting glucagon, epinephrine, cortisol, and growth hormone (GH) oppose the action of insulin thus promoting glycogenolysis, gluconeogenesis, and ketogenesis which result in hyperglycemia. Consequently, deficiency of these hormones may provoke hypoglycemia. However, it is not custom for counter-regulatory hormones deficiency to present with hypoglycemia as a sole manifestation. It commonly consists of a group of clinical signs and symptoms altogether (Cryer et al., 2009; Koren and Palladino, 2016). Hypercortisolism is a condition which resulted from the inability of adrenal glands to produce sufficient cortisol hormone and other steroid hormones such as aldosterone. Clinical manifestations of hypercortisolism cover weight loss, fatigue, postural hypotension, hyponatremia, normochromic anemia, lymphocytosis, and eosinophilia (Kasper et al., 2015). Epinephrine deficiency leads to primary autonomic nervous system failure and elevated dopamine which clinically manifest as orthostatic hypotension, ptosis, nasal congestion, exercise intolerance, and sexual disorders (Koren and Palladino, 2016). GH deficiency in adults may occur in 2 conditions: children

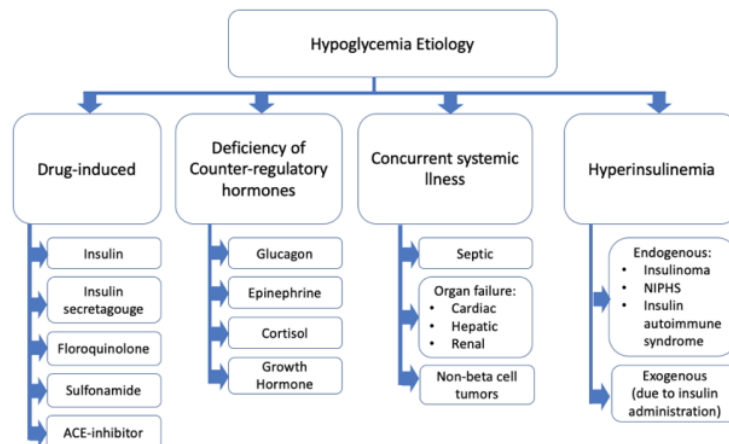


Figure 2. Etiology of Hypoglycemia

Table 2. Previous reports of hypoglycemia in HCC patients due to NICTH

Age	Sex	Clinical Presentation	Laboratory and Radiology Examination	Treatment	End Result	Reference
76	F	<ul style="list-style-type: none"> Episode of collapse Firm right upper quadrant mass 	<ul style="list-style-type: none"> Blood glucose 1 mmol/L Insulin <6 pmol/l (NR=12–150) C-peptide 0.19 nmol/l (NR=0.34–1.80) IGF-I 3.8nmol/l (NR=4.4–21.8) IGF-II/IGF-I ratio 11.0 (normal ≤10) CT scan: A large tumor in the right lobe of the liver without extrahepatic spread Percutaneous biopsy: HCC 	Palliative treatment covering: <ul style="list-style-type: none"> Nocturnal NG feeding of food rich in carbohydrates Prednisolone 40 mg gradually weaned to 20mg daily Somatostatin analogue 30 mg daily 	Patient passed away 3 months after discharge	(North et al., 2022)
71	M	<ul style="list-style-type: none"> Confused Diaphoretic Lightheaded 	<ul style="list-style-type: none"> Blood glucose 31 mg/dL Insulin 1.7 uIU/mL (NR≤19.6) C-peptide 0.00437 ng/L (NR=0.80–3.85) CT abdomen: Innumerable lesions throughout the liver compatible with multifocal hepatocellular carcinoma 	<ul style="list-style-type: none"> The patient had previously been treated with nivolumab for HCC and it was continued with the same dose. Glucose tablets and glucagon initially and subsequently the patient was maintained with prednisone 2 mg every 12 hours and a frequent diet plan 	Hypoglycaemia resolved but the patient passed away 5 months after due to COVID-19 related complications	(Sinha et al., 2023)
55	F	<ul style="list-style-type: none"> Aggressiveness Disorientation 	<ul style="list-style-type: none"> Cortisol 8.9 ug/dL (NR= 5.27-22.45) Blood glucose 17 mg/dL Insulin 0.40 uU/mL (NR=2.6-24.9) IGF-I<15 ng/mL (NR=45-210) C peptide 0.0407 ng/mL (NR=1.1- 4.4) PET/CT with 18-FDG: High FDG uptake index suggesting an elevated glucose consumption tumor 	<ul style="list-style-type: none"> TACE was performed twice with partial improvement Patient was subsequently provided with palliative care covering parenteral nutrition with a high dextrose load. 	Due to high tumor burden, various interventions were deemed to have low success rate, therefore, patient was provided with palliative care.	(Regino et al., 2020)
58	M	<ul style="list-style-type: none"> Headache, dizziness, and disorganized behavior Liver palpable 4 cm below the right rib 	<ul style="list-style-type: none"> Blood glucose 44 mg/dl Insulin 0.4 μU/mL (NR: 1.9 - 23) C-peptide: 0.355 ng/mL (NR:1.1 - 4.4) Cortisol: 12.2 ug/dL PET/CT with 18-FDG: A hypermetabolic lesion with heterogeneous increased FDG uptake observed in the liver 	<ul style="list-style-type: none"> TACE was performed twice and the second chemoembolization was given with lipiodol. Sorafenib 400 mg daily Physiological doses of prednisolone 	PET/CT evaluation observed significant decreased in vascularization of the mass and intra-mass stagnation. Hypoglycaemia is stabilized with physiological dose of steroid.	(Albayrak et al., 2022)

with GH transitioning to adult and deficiency acquired during adulthood due to trauma or idiopathic. Symptoms of GH

deficiency include low energy level, emotional lability, mental fatigue, decreased muscle mass, and decreased bone density (Pia et al., 2004; Gupta, 2011). Due to the absence of clinical features described above which complements the patient's hypoglycemic episodes, related hormone examinations were deemed unnecessary.

Hyperinsulinemia hypoglycemia can be classified as endogenous and exogenous due to insulin administration. The former mainly covers insulinoma, non-insulinoma pancreatogenesis hypoglycemia syndrome (NIPHS), and insulin autoimmune syndrome. Ideally, in ²⁹ examinations to screen for hyperinsulinemia should consist of plasma insulin, C-peptide, pro-insulin, and β -hydroxybutyrate concentration (Martens and Tits, 2014). However, due to the limited resource, it was decided to test insulin level first. Given the low insulin result, hyperinsulinemia was eventually ruled out.

Anamnesis and past examinations have narrowed differential diagnosis to concurrent systemic illness or paraneoplastic syndrome from non-beta cell tumor. Liver failure, renal failure, and sepsis are the most common systemic critical illness which may cause hypoglycemia. Renal failure may cause impairment in insulin clearance while sepsis releases various cytokines inducing glucose utilization of which both conditions are not found in this patient (Martens and Tits, 2014). Liver failure contributes to hypoglycemia mainly through anatomical and hepatocytes injury resulting in gluconeogenesis impairment, diminished insulin production, and decreased insulin uptake by liver cells. Nonetheless, hypoglycemia is more likely to develop in massive hepatocytes necrosis. A study in China suggested that Child-Pugh grade C, higher AFP, and low HbA1c significantly increase the likelihood of hypoglycemia in the population (Zheng et al., 2021). In this case, the absence of chronic liver disease stigmata with a normal albumin and coagulation blood test have put the patient in a compensated liver state. Therefore, it was reasonable to consider paraneoplastic syndrome as the possible main cause of the refractory hypoglycemia in this patient.

Non-beta cell tumor causing hypoglycemia, referred as non-islet cell tumor hypoglycemia (NICTH), is a rare paraneoplastic phenomenon of which prevalence not clearly known and most cases tend to be underdiagnosed. NICTH occurs when a tumor overly produces incomplete processed insulin growth factor-II (IGF-II) also known as pro-IGF-II or big IGF-II because it has high molecular weight. It may origin from solid tumors, hematopoietic, and neuroendocrine malignancies (De Groot et al., 2007; Iglesias and Díez, 2014). IGF-II is a peptide hormone normally secreted in the liver which is structurally homologous to insulin. Similar to insulin, IGF-II has the ability to induce hypoglycemia by increasing glucose consumption in skeletal muscle, suppressing hepatic glucose production, and suppressing lipolysis in adipose tissue. High circulating IGF-II also gives negative feedback to the pituitary causing a decrease in GH production (Hu et al., 2009; Dynkevich et al., 2013; Khowaja et al., 2014; Garlat, 2018). The gold standard for NICTH diagnosis is measurement of big IGF-II through chromatography which is expensive and not widely available. Total IGF-II assay alone is not valuable because it measures combination of big IGF-II and the mature variant of IGF-II which does not play major part in NICTH pathogenesis. An alternative ¹¹ diagnostic method to choose is IGF-II/IGF-I ratio. A high level of IGF-II is known to activate IGF-I

receptors resulting in suppressed IGF-1, therefore, ratio of IGF-II/IGF-I ratio > 10 suggests diagnosis of NICTH. A positron emission tomography/computerized tomography (PET/CT) with fluorine-18-fluorodeoxyglucose (18-FDG) is an imaging method to evaluate possible glucose uptake by a tumor. However, high uptake of FDG may result from skeletal and cardiac muscles resulting in a false negative result (Dutta et al., 2013; Garla et al., 2019).

The characteristics of HCC patients presenting with hypoglycemia who had been suspected or diagnosed with NICTH are presented in **Table 2**. Of the 4 cases we displayed, one case was able to display elevated IGF-II/IGF-I ratio to support NICTH diagnosis; two cases suggested high FDG uptake from PET/CT scan; and one case did not proceed with specific diagnostic method for NICTH as mentioned above. All cases presented with low insulin and low C-peptide and none of them used chromatography ¹¹ method. Our case was found to have low insulin; however, IGF-I and IGF-II assays were unavailable.

Despite the etiology, the main goal of treating hypoglycemia is to immediately achieve and sustain euglycemia. This can be accomplished by administration of glucose orally or intravenously. Other choices of therapy include glucocorticoid, glucagon, somatostatin analogues, and recombinant human GH (rhGH) (De Groot et al., 2007; Iglesias and Díez, 2014). A more definitive treatment aimed at the underlying tumor should be considered to prevent recurrent hypoglycemic episodes. The definitive therapeutic choice for both HCC and NICTH is surgical resection where resolution of hypoglycemia has been exhibited in cases after subtotal or total tumor resection. However, there are conditions in which resection may not be possible, for example large tumor size, widespread metastasis, severe illness, and patient's preference. In this circumstances, other local antitumor therapy like chemotherapy, embolization, or radiation may be considered with varying success rate (Thomas and Kumar, 2013; Bodnar et al., 2014).

Due to the extensive size of the tumour, surgical resection was not feasible option for our patient. Considering his ill condition, he preferred palliative and supportive treatment. NICTH independently predicts poor prognosis in patients with HCC. Along with other forms of paraneoplastic syndromes, it has a mean survival time approximately 36 days (Kew, 2016). The studies presented in table 2 suggest that tumour-targeting therapies such as TACE and sorafenib alleviate hypoglycaemia episodes notably in patients not qualified for surgery. Currently, there is no recommendation for diet regimens particularly in palliative care, however, cases with favourable outcome proposed that diet can be maintained not only through nasogastric feeding but also via parenteral access. Most cases require maintenance of steroid slowly weaned down to the physiological dose and glucose tablets.

Conclusion

This case report highlights the difficulty of determining true etiology of hypoglycemia in non-diabetic patients given that most require advanced diagnostic tools. Deciding what diagnostic modalities needed to perform to establish the diagnosis eventually relies on clinical judgement while taking cost-effectiveness and patients' preference in consideration,

particularly in low-resource settings. Our analysis has put NICTH as the possible main cause. Nonetheless, future assessment would require IGF-II/IGF-I ratio examination or chromatography if possible.

Author Contribution

The first author is responsible for construction of the manuscript, data analysis, literature review, and critical review; the second author is responsible for Execution of patient follow-up, management and reporting, data analysis; and the third author is responsible for critical review and supervising the course of article.

28

Conflict of interest

The authors declare no conflict of interest.

Acknowledgments

The authors would like to thank Dr. Soetomo General Hospital.

Reference

- Albayrak, B., Duman, M. B., and Ayvaz, E. (2022). A Case of Hepatocellular Carcinoma Diagnosed with Resistant Hypoglycemia. *Open J. Gastroenterol.* 12, 179–185.
- Bansal, N., and Weinstock, R. S. (2020). Non-diabetic hypoglycemia. *Endotext [Internet]*.
- Bodnar, T. W., Acevedo, M. J., and Pietropaolo, M. (2014). Clinical Review: Management of Non-Islet-Cell Tumor Hypoglycemia: A Clinical Review. *J. Clin. Endocrinol. Metab.* 99, 713.
- Cryer, P. E., Axelrod, L., Grossman, A. B., Heller, S. R., Montori, V. M., Seaquist, E. R., et al. (2009). Evaluation and management of adult hypoglycemic disorders: an Endocrine Society Clinical Practice Guideline. *J. Clin. Endocrinol. Metab.* 99, 709–728.
- De Groot, J. W. B., Rijkhof, B., van Doorn, J., Biló, H. J. G., Alleman, M. A., Honkoop, A. H., et al. (2007). Non-islet cell tumour-induced hypoglycaemia: a review of the literature including two new cases. *Endocr. Relat. Cancer* 14, 979–993.
- Dutta, P., Aggarwal, A., Gogate, Y., Nahar, U., Shah, V. N., Singla, M., et al. (2013). Non-islet cell tumor-induced hypoglycemia: a report of five cases and brief review of the literature. *Endocrinol. Diabetes Metab. Case Reports* 2013.
- Dynkevich, Y., Rother, K. I., Whitford, I., Qureshi, S., Galiveeti, S., Szulc, A. L., et al. (2013). Tumors, IGF-2, and hypoglycemia: insights from the clinic, the laboratory, and the historical archive. *Endocr. Rev.* 34, 798–826.
- Garla, V., Sonani, H., Palabindala, V., Gomez-Sanchez, C., Subauste, J., and Lien, L. F. (2019). Non-islet cell hypoglycemia: case series and review of the literature. *Front. Endocrinol. (Lausanne)*. 10, 316.
- Garlat, V. (2018). Non Islet Cell Hypoglycemia. *Creat. Commons Attrib. 4.0*. Available at: <http://www.smgebooks.com/hypoglycemia-causes-occurrences/chapters/HG-18-05.pdf> [Accessed December 21, 2018].
- Gupta, V. (2011). Adult growth hormone deficiency. *Indian J. Endocrinol. Metab.* 15 Suppl 3, S197–S202. doi:10.4103/2230-8210.84865.
- Hu, M., Yeung, S., and Gagel, R. (2009). "Endocrine paraneoplastic syndromes," in *Medical Care of Cancer Patients*, eds. S. Yeung, C. Escalante, and R. Gagel (Connecticut: People's Medical Publishing House).
- Iglesias, P., and Díez, J. J. (2014). Management of endocrine disease: a clinical update on tumor-induced hypoglycemia. *Eur. J. Endocrinol.* 170, R147–R157.
- Kasper, D. L., Fauci, A. S., Hauser, S. L., Longo, D. L., Jameson, J. L., and Loscalzo, J. (2015). *Harrison's principles of internal medicine*. 19th ed. New York: McGraw Hill Education.
- Kew, M. C. (2016). Paraneoplastic phenomena in patients with hepatocellular carcinoma. *J Liver Res Disord Ther* 2, 9–12.
- Khowaja, A., Johnson-Rabbett, B., Bantle, J., and Moheet, A. (2014). Hypoglycemia mediated by paraneoplastic production of Insulin like growth factor–2 from a malignant renal solitary fibrous tumor—clinical case and literature review. *BMC Endocr. Disord.* 14, 49.
- Koren, D., and Palladino, A. (2016). "Hypoglycemia," in *Genetic Diagnosis of Endocrine Disorders* (Elsevier), 31–75.
- Levrero, M., and Zucman-Rossi, J. (2016). Mechanisms of HBV-induced hepatocellular carcinoma. *J. Hepatol.* 64, S84–S101.
- Martens, P., and Tits, J. (2014). Approach to the patient with spontaneous hypoglycemia. *Eur. J. Intern. Med.* 25, 415–421.
- McGlynn, K. A., Petrick, J. L., and El-Serag, H. B. (2021). Epidemiology of hepatocellular carcinoma. *Hepatology* 73, 4–13.
- North, A. S., Tikkar, R. G., James, R. A., and Hammond, J. S. (2022). The palliative management of non-islet cell tumour hypoglycaemia with glucocorticoids and somatostatin analogues in an unresectable hepatocellular carcinoma. *Ann. R. Coll. Surg. Engl.* 104, e180–e182.
- Peloso, L. C., and Gerber, D. E. (2010). Paraneoplastic syndromes: An approach to diagnosis and treatment. in *Mayo Clinic Proceedings* (Elsevier), 838–854.
- Pia, A., Piovesan, A., Tassone, F., Razzore, P., Visconti, G., Magro, G., et al. (2004). A rare case of adulthood-onset growth hormone deficiency presenting as sporadic, symptomatic hypoglycemia. *J. Endocrinol. Invest.* 27, 1060–1064.
- Regino, C. A., López-Montoya, V., López-Urbano, F., Alvarez, J. C., and Roman-Gonzalez, A. (2020). Paraneoplastic hypoglycemia in hepatocarcinoma: case report and literature review. *Cureus* 12.
- Sinha, S., Ahluwalia, A., and Wasserman, C. (2023). Non-islet cell tumor causing hypoglycemia: A paraneoplastic complication of hepatocellular carcinoma. *J Case Rep Images Oncol.* 9, 15–18.
- Thomas, J., and Kumar, S. C. (2013). Nonislet cell tumor hypoglycemia. *Case Rep. Endocrinol.* 2013.
- Zheng, X., Yan, H., Gan, B., Qiu, X.-T., Qiu, J., Zhang, J., et al. (2021). Incidence and risk factors for hypoglycemia in patients with hepatocellular carcinoma.

Pendekatan Klinis Hipoglikemia Berulang pada Pasien dengan Karsinoma Sel Hati: Laporan Kasus dan Tinjauan Kepustakaan

ORIGINALITY REPORT

14%

SIMILARITY INDEX

%

INTERNET SOURCES

12%

PUBLICATIONS

9%

STUDENT PAPERS

PRIMARY SOURCES

- 1** Uci Intan Permatasari, Asyhara Naela Arifin. "Hubungan Lama Dan Masa Kerja Terhadap Risiko Terjadinya Carpal Tunnel Syndrome (CTS) Pada Staff Administrasi Pengguna Komputer: Narrative Review", *Journal Physical Therapy UNISA*, 2021 **1** %

Publication
- 2** Daniel J. Przybylski, Ruemu Birhiray, David J. Reeves. "Severe Hypoglycemia Caused by Lenalidomide", *Pharmacotherapy: The Journal of Human Pharmacology and Drug Therapy*, 2018 **1** %

Publication
- 3** Submitted to Western Governors University **1** %

Student Paper
- 4** Alejandro Rosell Castillo, Aglecio Luiz de Souza, Sarah Monte Alegre, Yeelen Ballesteros Atala et al. "Insulin Sensitivity Is Not Decreased in Adult Patients With

Hypopituitarism Without Growth Hormone Replacement", *Frontiers in Endocrinology*, 2019

Publication

5	Submitted to Student Paper	1 %
6	Michael C. Onyema, Eftychia E. Drakou, Georgios Giovos, Bianca Leca et al. "Paraneoplastic hypoglycaemia secondary to IGF-2 secretion from a metastatic gastrointestinal stromal tumour", <i>Endocrine and Metabolic Science</i> , 2020 Publication	1 %
7	Submitted to Flinders University Student Paper	1 %
8	Submitted to University of Liverpool Student Paper	1 %
9	Ying Hu, Tahereh Setayesh, Farzam Vaziri, Xuesong Wu, Samuel T. Hwang, Xin Chen, Yu-Jui Yvonne Wan. "miR-22 gene therapy treats HCC by promoting anti-tumor immunity and enhancing metabolism", <i>Molecular Therapy</i> , 2023 Publication	1 %
10	Submitted to London Metropolitan University Student Paper	<1 %

11 Molecular and Cellular Biology of Insulin-like Growth Factors and Their Receptors, 1989. <1 %
Publication

12 Submitted to University of South Alabama <1 %
Student Paper

13 S Akif, K Parmar, S Kumar, RM Mavuduru, A Bal. "Small renal mass with large lymph nodal metastasis and inferior vena cava thrombus: an exceptional amalgamation", The Annals of The Royal College of Surgeons of England, 2022 <1 %
Publication

14 Submitted to University of Edinburgh <1 %
Student Paper

15 Maria Francesca Armentano, Marianna Caterino, Rocchina Miglione, Angela Ostuni et al. "New insights on the functional role of URG7 in the cellular response to ER stress", Biology of the Cell, 2018 <1 %
Publication

16 XiaoJing Zheng, Hong-Hong Yan, Bin Gan, Xiao-Ting Qiu, Jie Qiu, Jing Zhang, Xiao-Ming Chen, Cui-Juan Huang, xumei Chen. "Incidence and risk factors for hypoglycemia in patients with hepatocellular carcinoma", Research Square Platform LLC, 2021 <1 %
Publication

17

Akira Shimatsu, Hitoshi Ishii, Hiromi Nishinaga, Osamu Murai, Kazuo Chihara. "Safety and effectiveness of long-term growth hormone therapy in Japanese patients with adult growth hormone deficiency: a postmarketing, multicenter, observational study", Endocrine Journal, 2017

Publication

<1 %

18

Koren, Dorit, and Andrew Palladino. "Hypoglycemia", Genetic Diagnosis of Endocrine Disorders, 2016.

Publication

<1 %

19

Mette Ejrnaes, Matthias G. von Herrath, Urs Christen. "Cure of Chronic Viral Infection and Virus-Induced Type 1 Diabetes by Neutralizing Antibodies", Clinical and Developmental Immunology, 2006

Publication

<1 %

20

Submitted to Universitas PGRI Adi Buana Surabaya

Student Paper

<1 %

21

Submitted to University of Newcastle

Student Paper

<1 %

22

Mohammad Javad Fallahi, Pariya Kouhi, Seyed Amir Sadrzadeh, Mansoureh Shokripour, Massood Hosseinzadeh. "Localized Pneumocystis jirovecii pneumonia in a

<1 %

malnourished, non-HIV- infected man in the absence of any established or diagnosed immunosuppressive condition: a case report", Springer Science and Business Media LLC, 2024

Publication

23

Submitted to Queen Mary and Westfield College

Student Paper

<1 %

24

Submitted to iHeed

Student Paper

<1 %

25

Michael C Kew. "Paraneoplastic Phenomena in Patients with Hepatocellular Carcinoma", Journal of Liver Research, Disorders & Therapy, 2016

Publication

<1 %

26

Submitted to University of Minnesota System

Student Paper

<1 %

27

Vella, Adrian, Robert A. Rizza, and F. John Service. "Hypoglycemia and Pancreatic Islet Cell Disorders", Goldman s Cecil Medicine, 2012.

Publication

<1 %

28

Kai O. Hensel, Julio C. Rendon, Maria-Cristina Navas, Marianne G. Rots, Jan Postberg. "Virus-host interplay in hepatitis B virus

<1 %

infection and epigenetic treatment strategies", The FEBS Journal, 2017

Publication

29

F.J. Service. "Hypoglycemic Disorders", New England Journal of Medicine, 04/27/1995

Publication

<1 %

30

Endalamaw Tesfa, Abaineh Munshea, Endalkachew Nibret, Daniel Mekonnen, Mulusew Alemneh Sinishaw, Solomon Tebeje Gizaw. "Evaluation of maternal serum lipid profiles and clinical chemistry parameters in the prediction of pre-eclampsia in pregnant women attending ANC and delivery services", Research Square Platform LLC, 2022

Publication

<1 %

31

Ryuta Fukai, Yoshihito Irie, Hiroyoshi Watanabe. "Surgically cured paraneoplastic hypoglycemia associated with solitary fibrous tumor of the pleura: report of two cases", Clinical Case Reports, 2017

Publication

<1 %

Exclude quotes Off

Exclude matches Off

Exclude bibliography Off